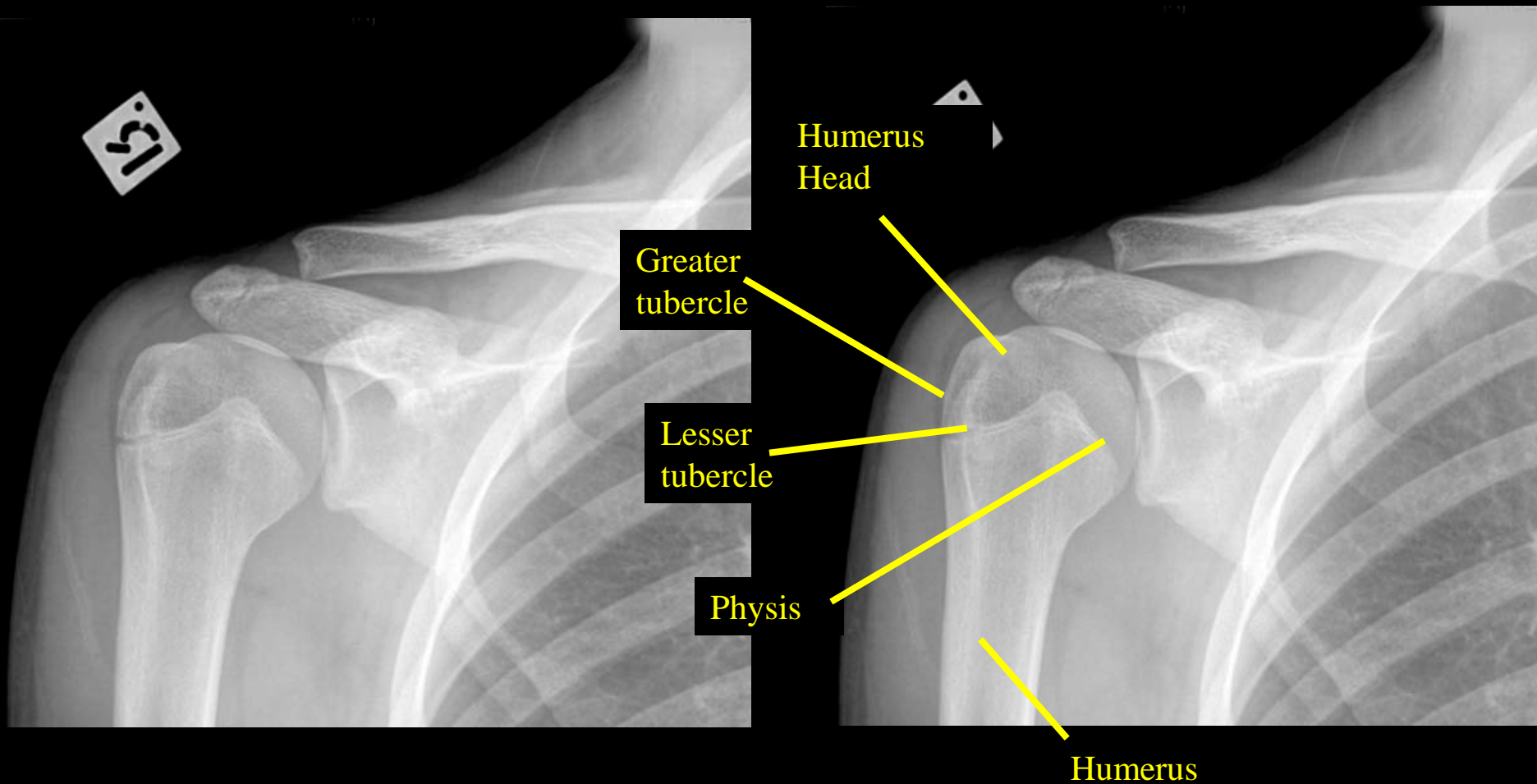
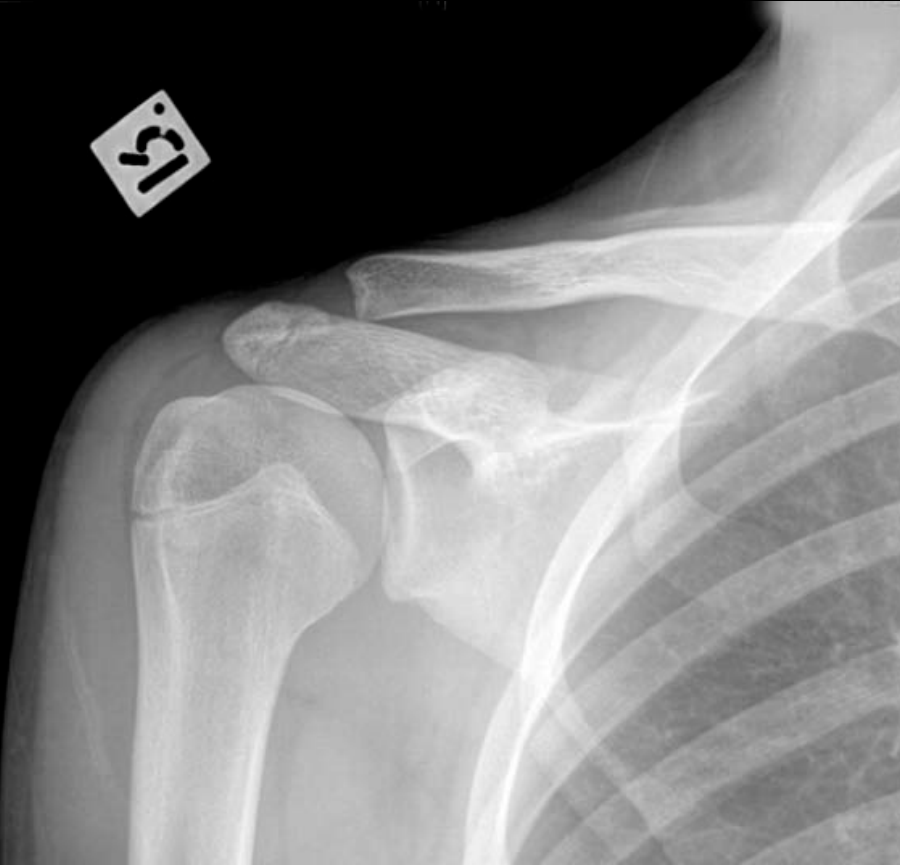

Pediatric Shoulder AP view (Humeral Head)

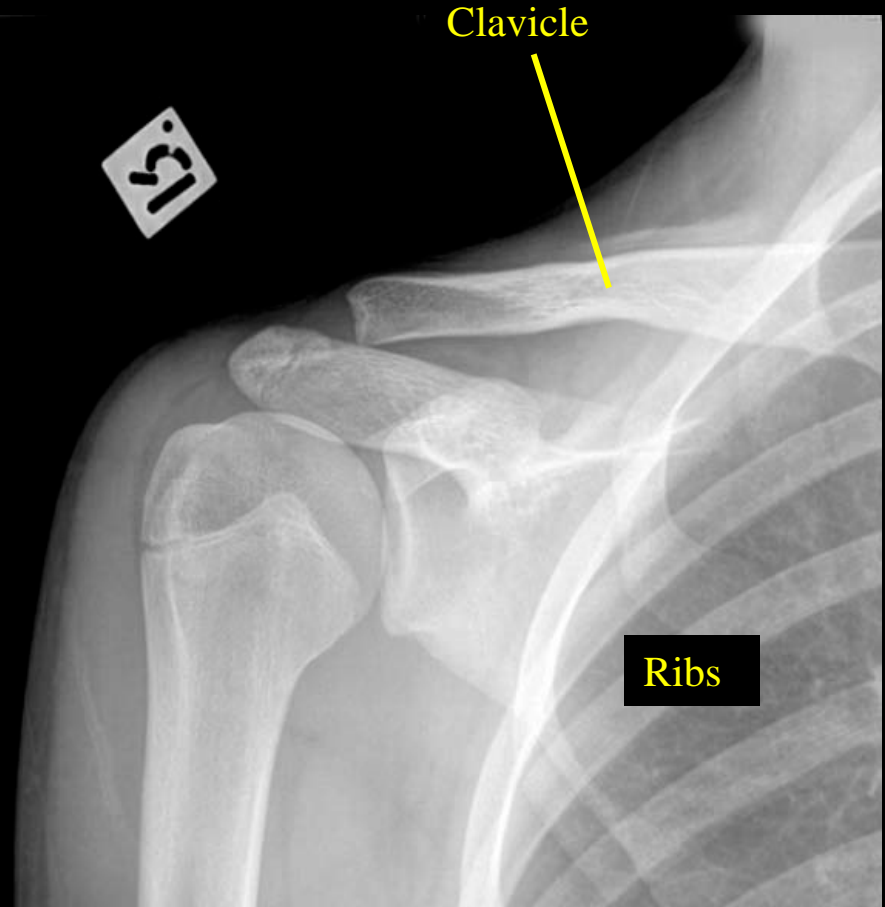


Pediatric Shoulder AP (Clavicle)

51



51



Clavicle

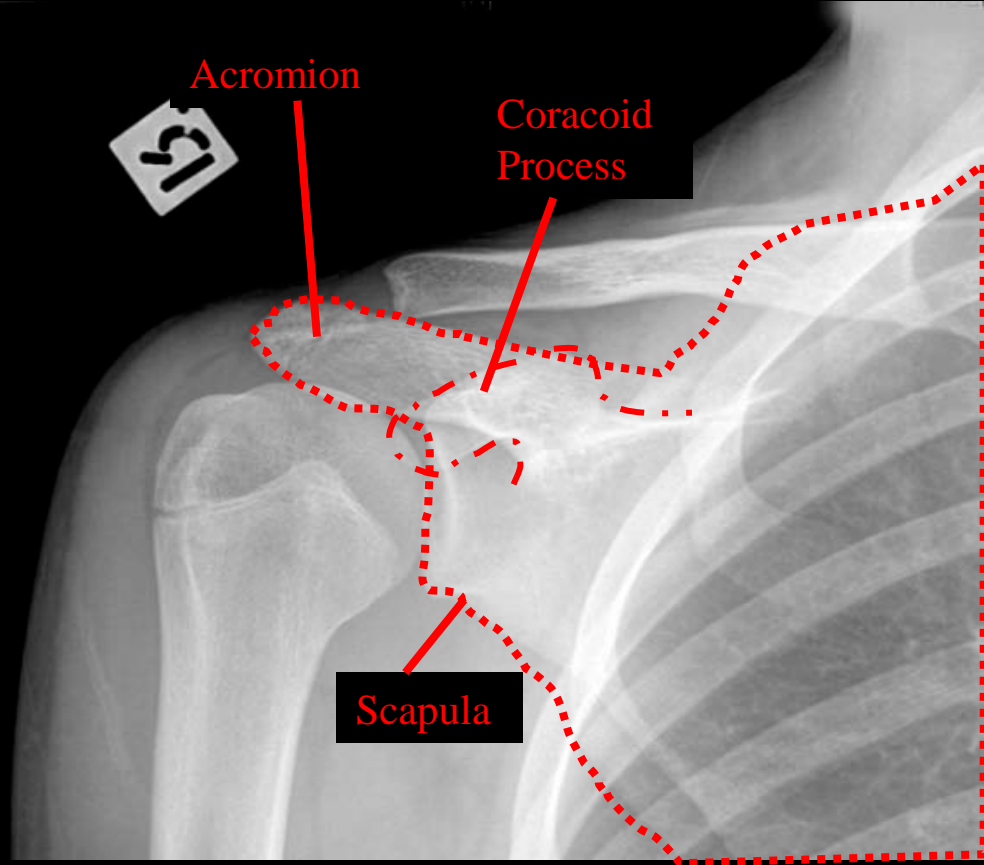
Ribs

Pediatric Shoulder AP

51



51

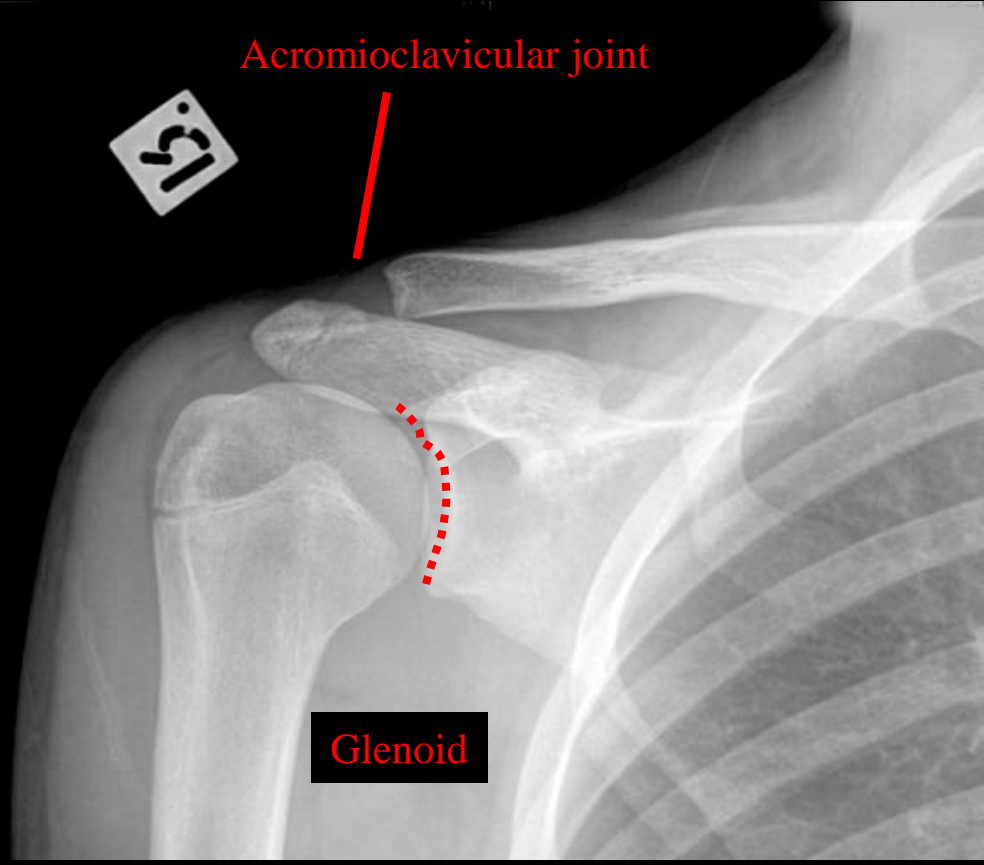


Acromion

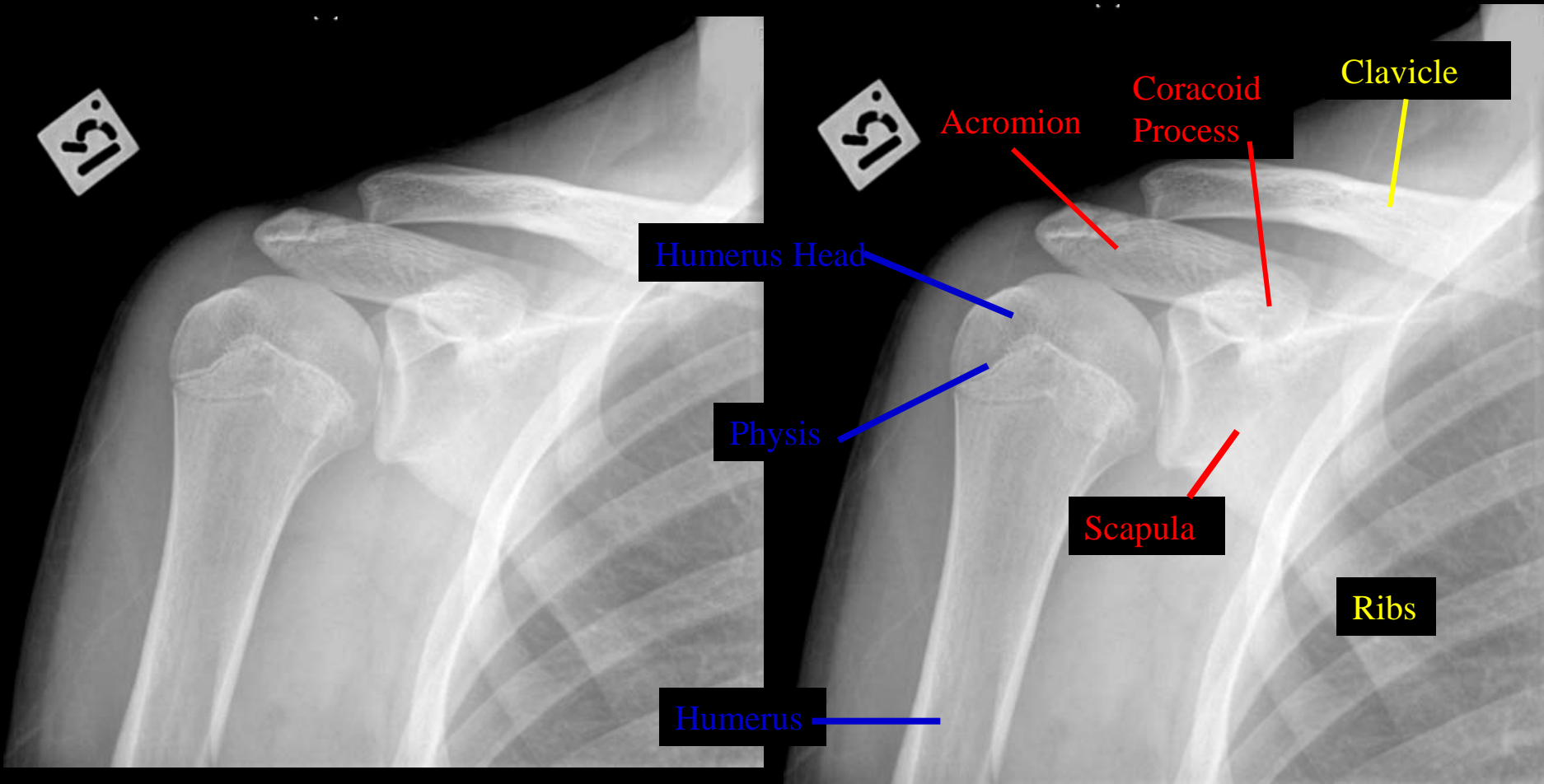
Coracoid Process

Scapula

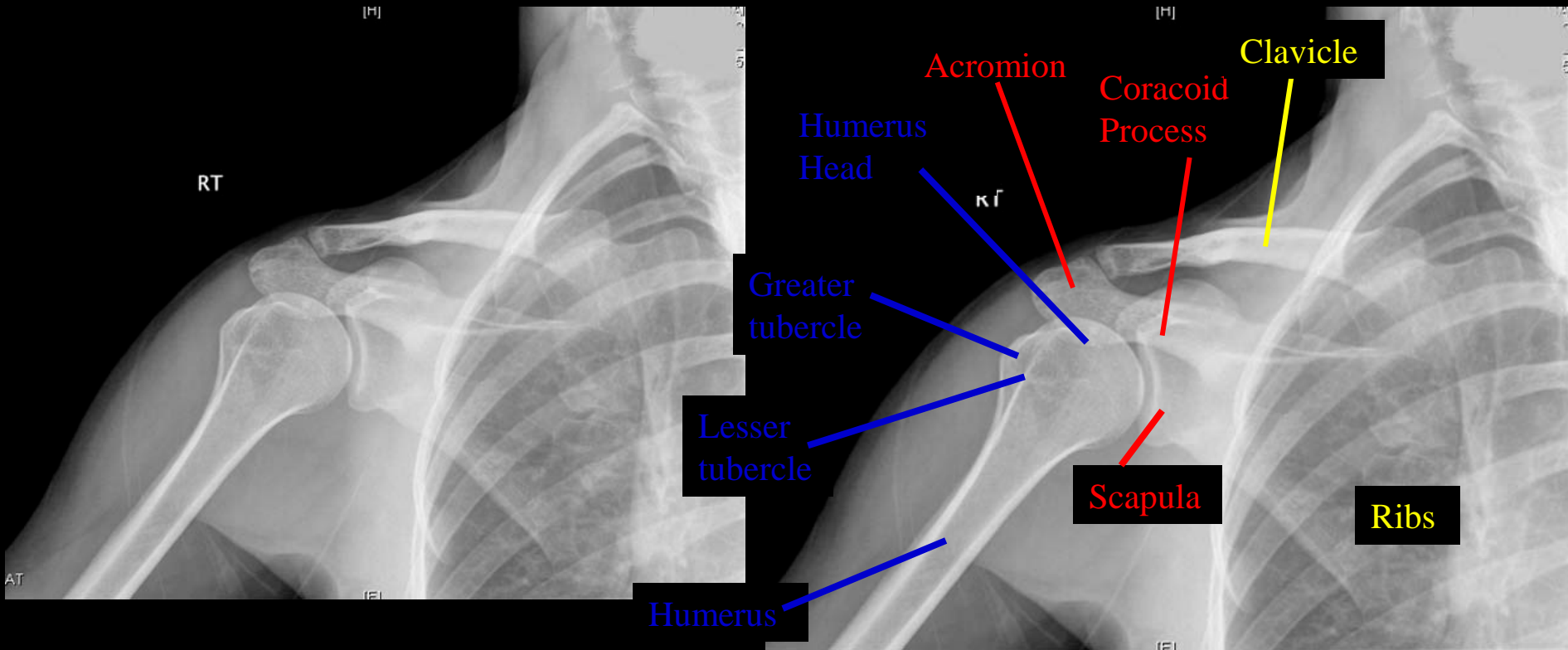
Pediatric Shoulder AP (AC Joint)



Pediatric Shoulder Internal Rotation

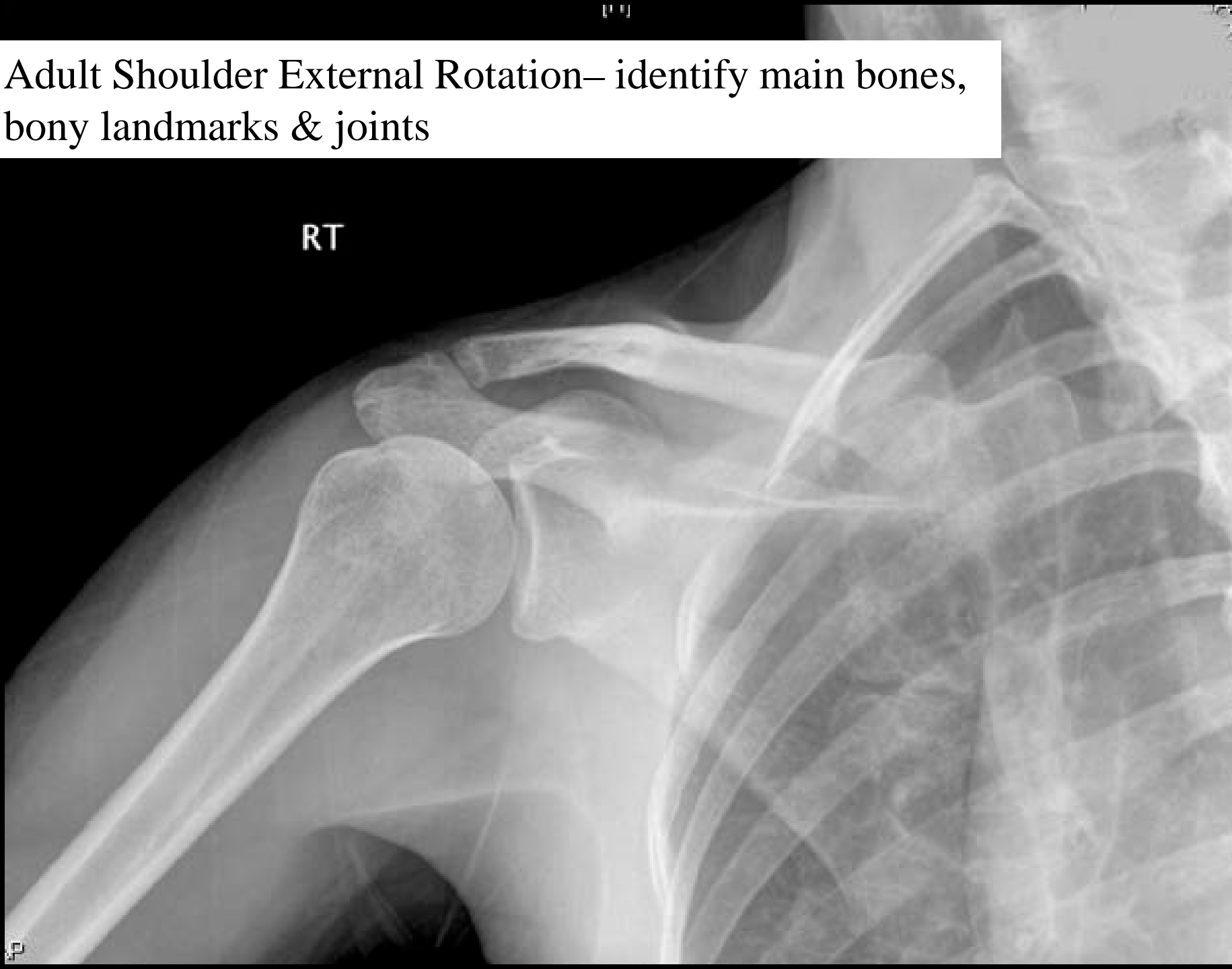

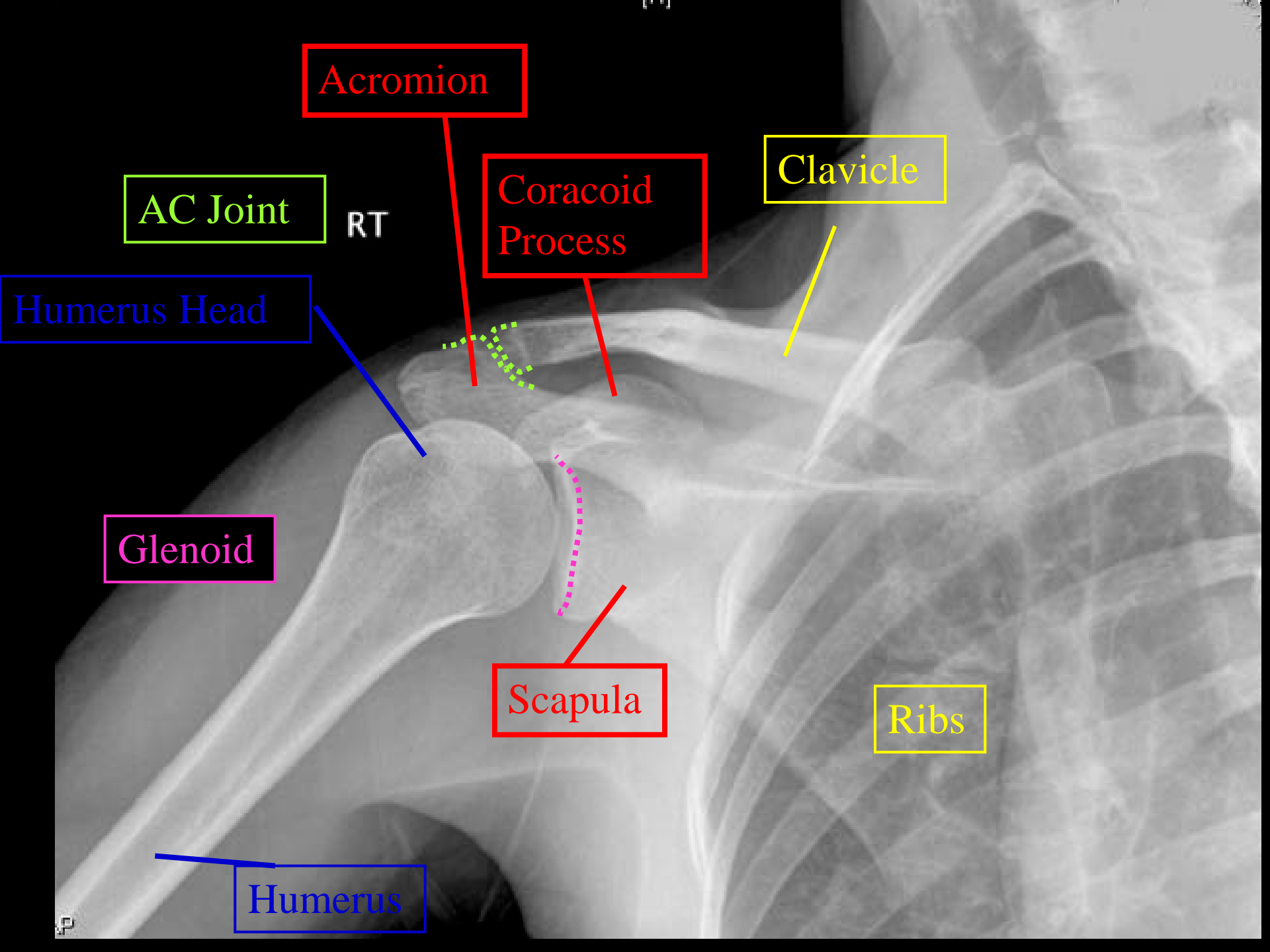
Adult Shoulder External Rotation



Adult Shoulder External Rotation– identify main bones,
bony landmarks & joints

RT





Acromion

AC Joint

RT

Coracoid Process

Clavicle

Humerus Head

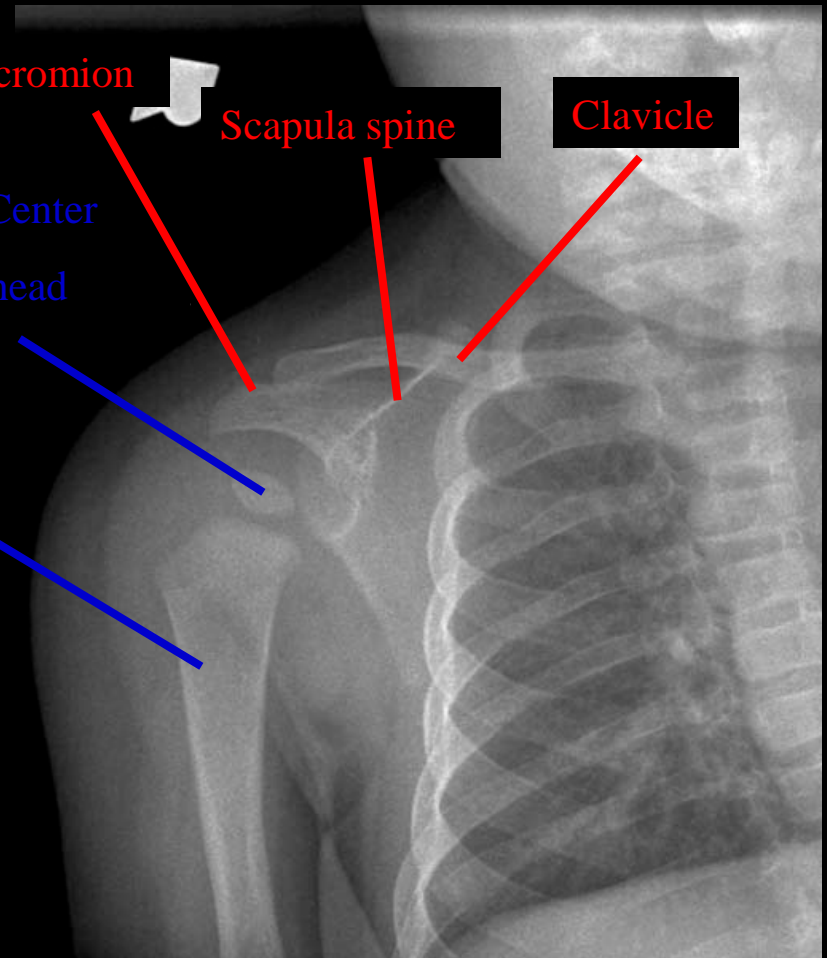
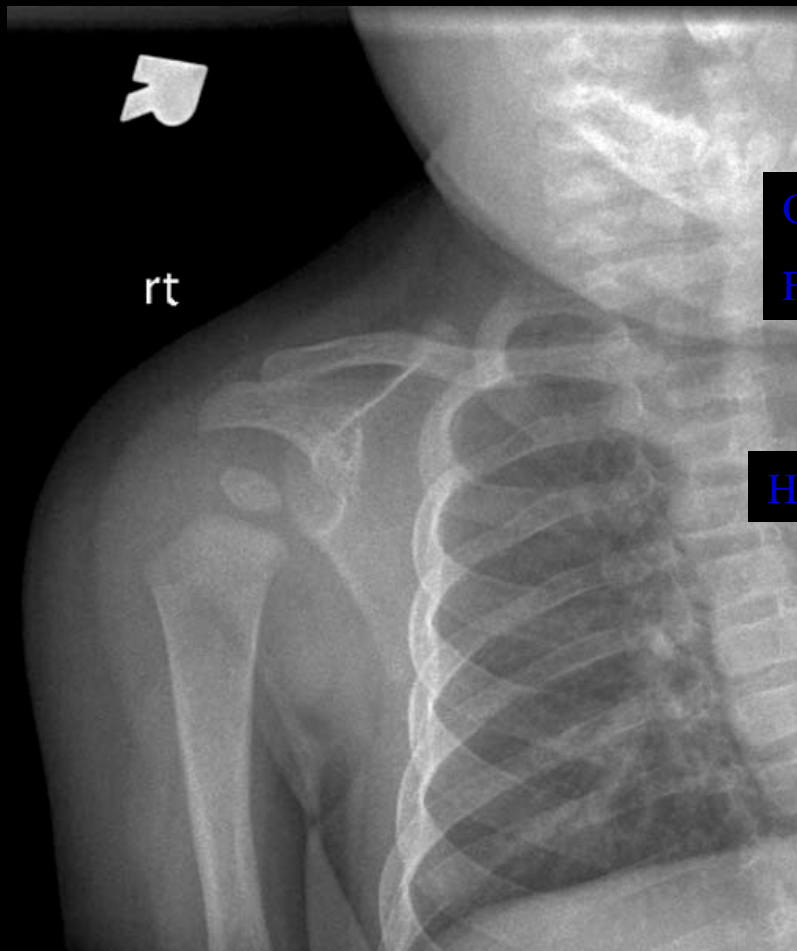
Glenoid

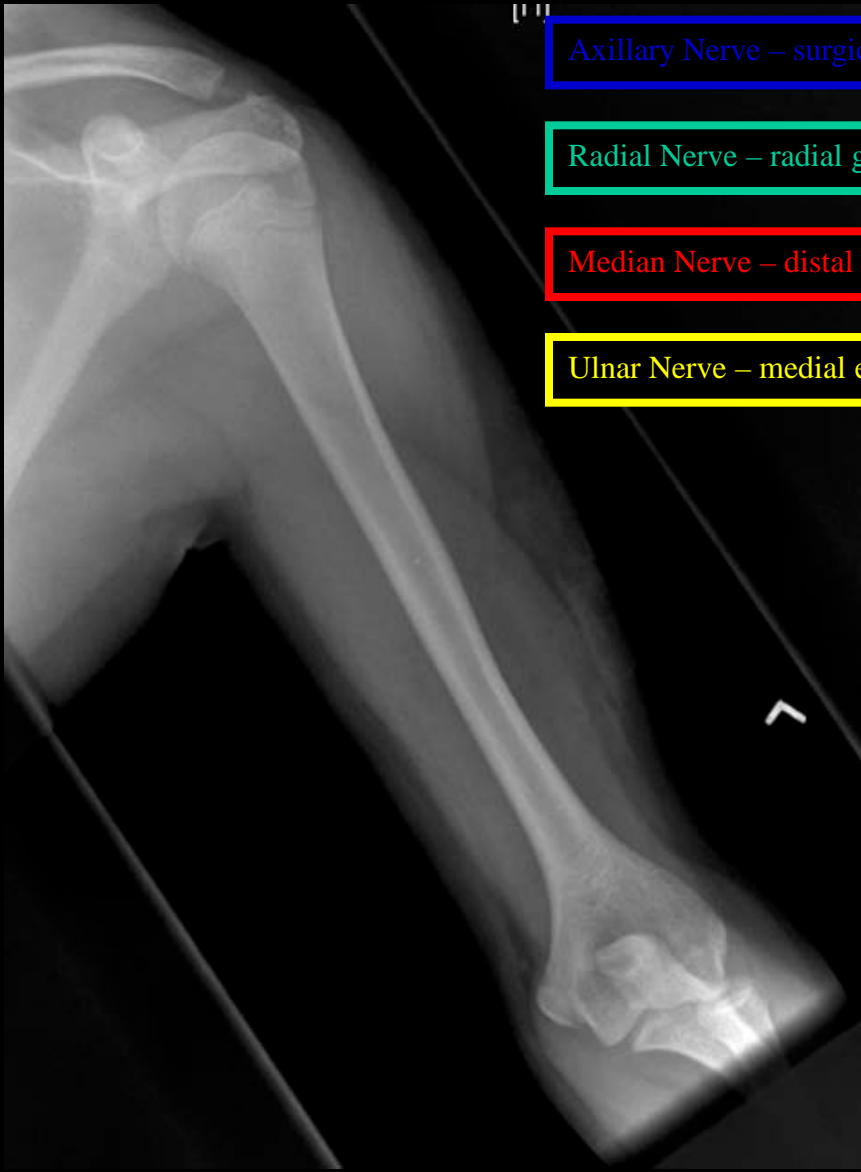
Scapula

Ribs

Humerus

Pediatric Shoulder AP



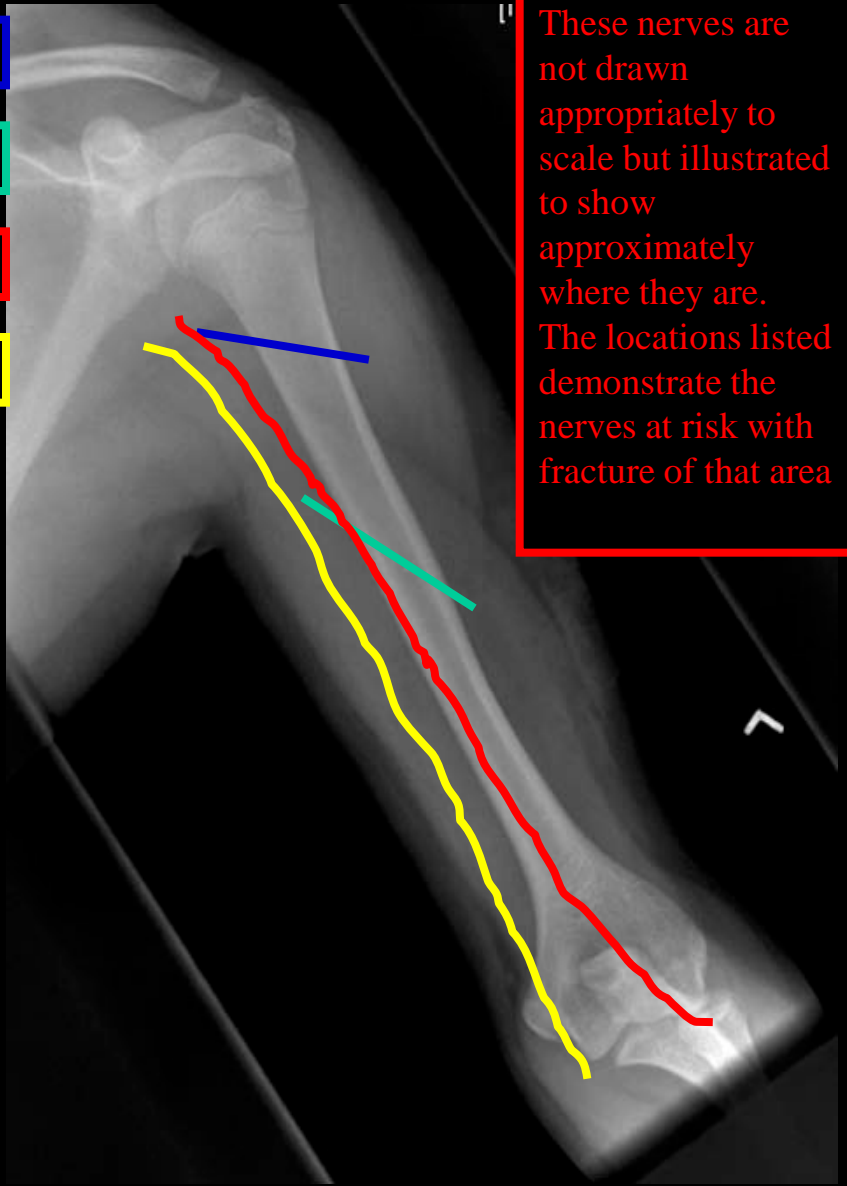


Axillary Nerve – surgical neck

Radial Nerve – radial groove

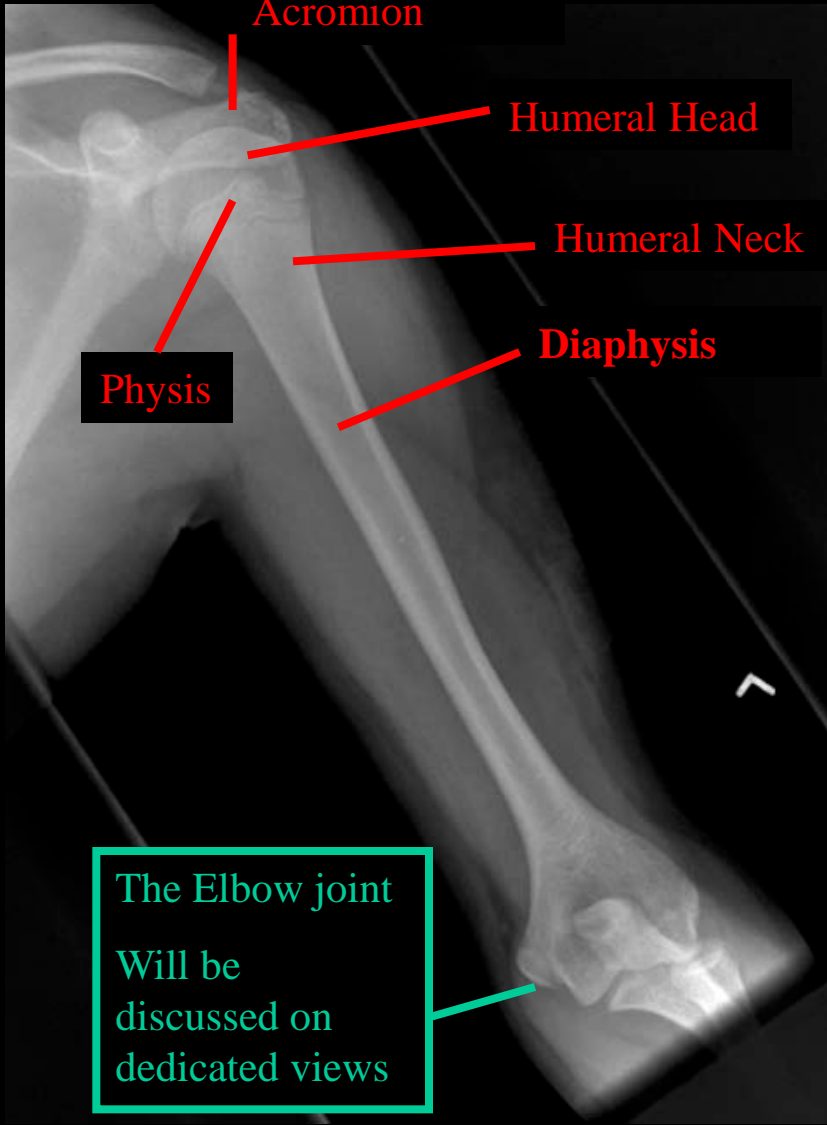
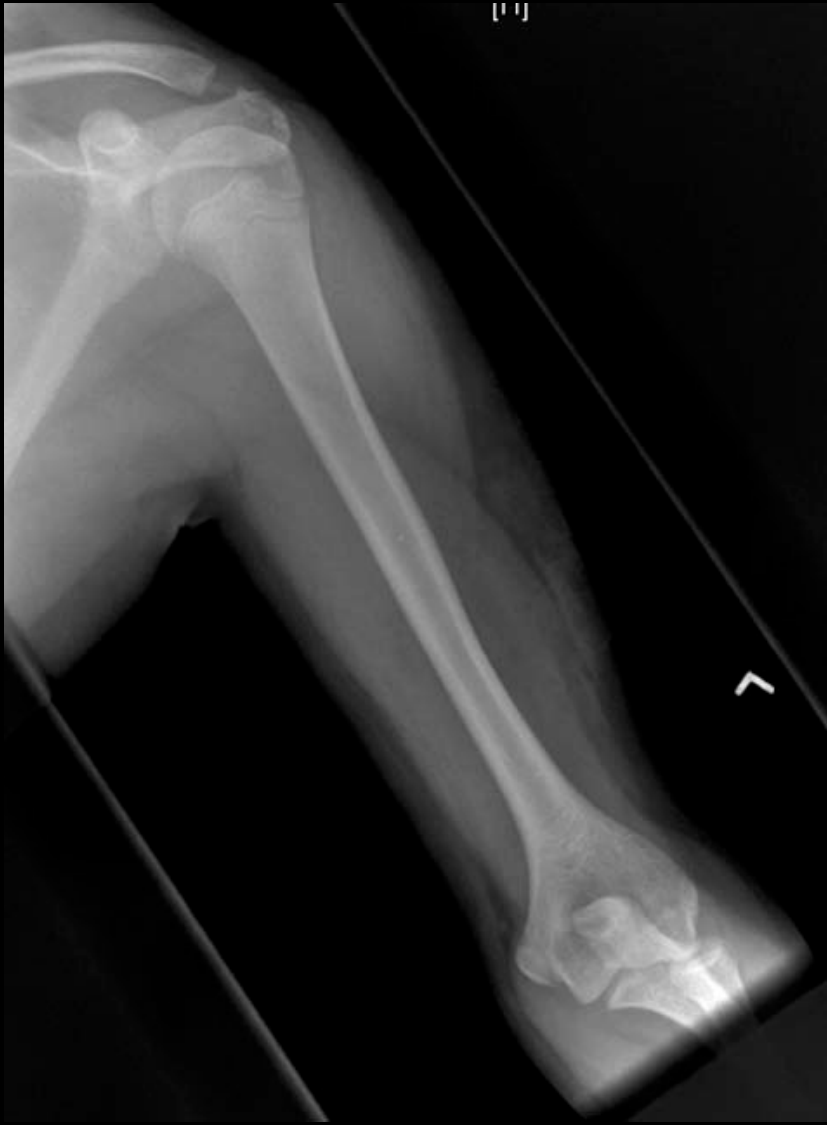Median Nerve – distal humerus

Ulnar Nerve – medial epicondyle

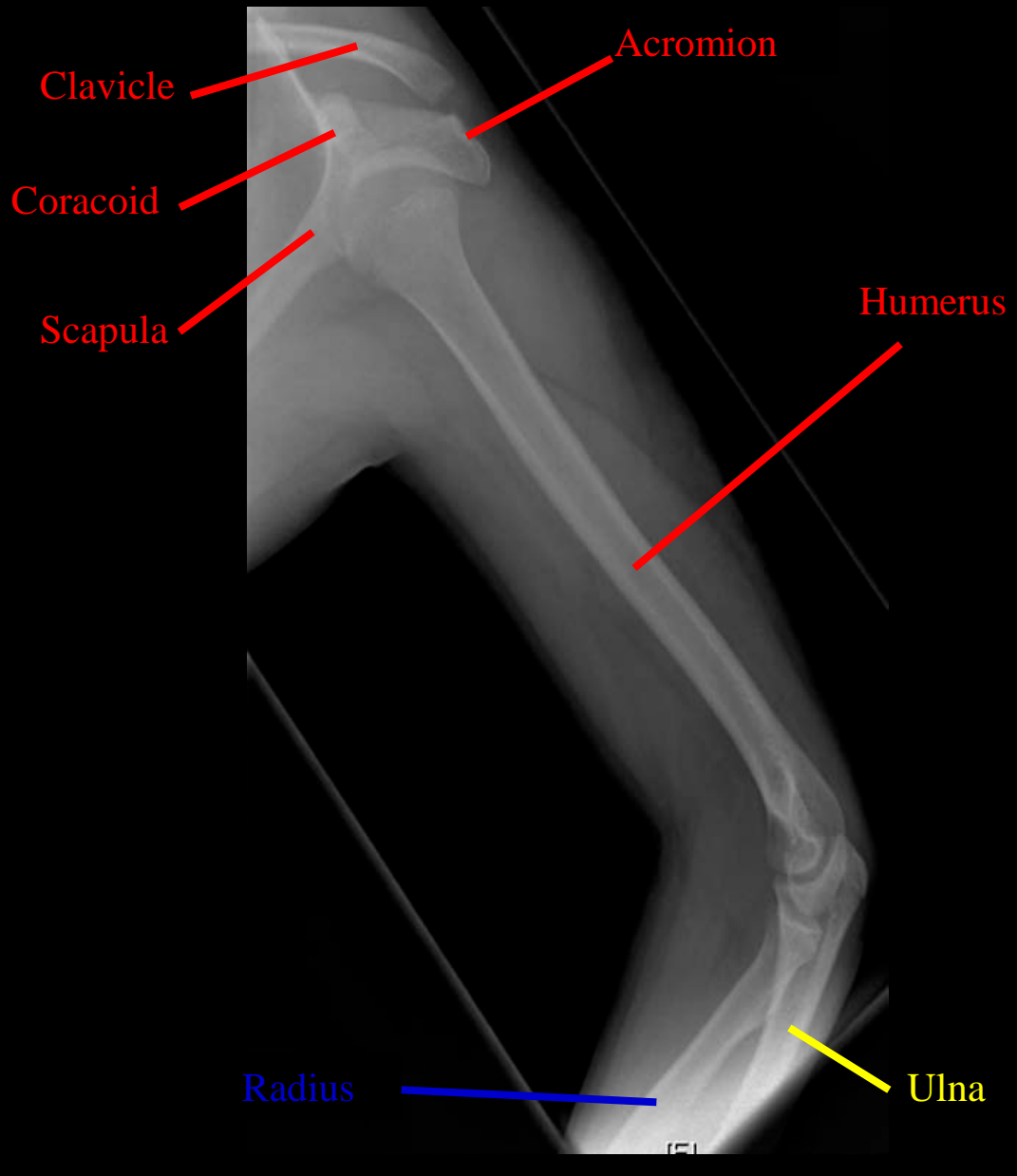
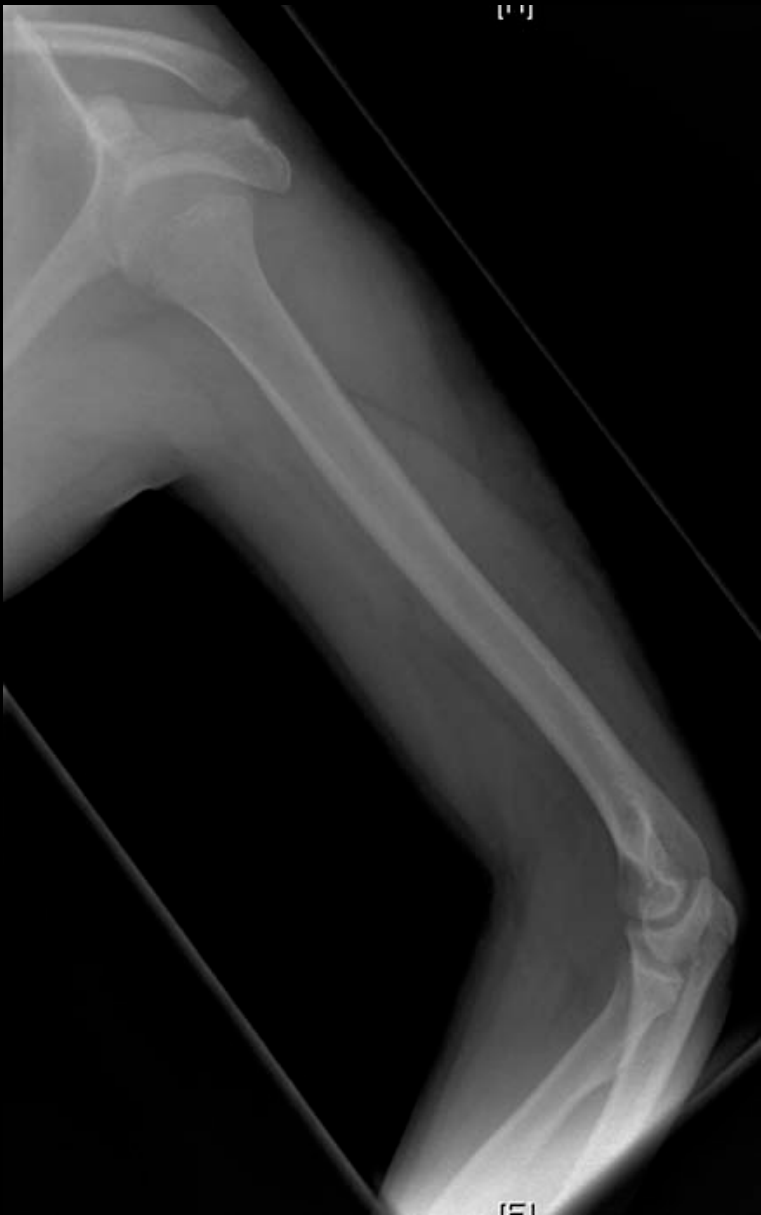

These nerves are not drawn appropriately to scale but illustrated to show approximately where they are. The locations listed demonstrate the nerves at risk with fracture of that area

Pediatric Humerus AP Nerves



Pediatric Humerus AP



Humerus Lateral

Humerus

Olecranon Fossa

Capitulum

Lateral epicondyle

Medial epicondyle

Radial tuberosity

Coronoid process

Trochlea

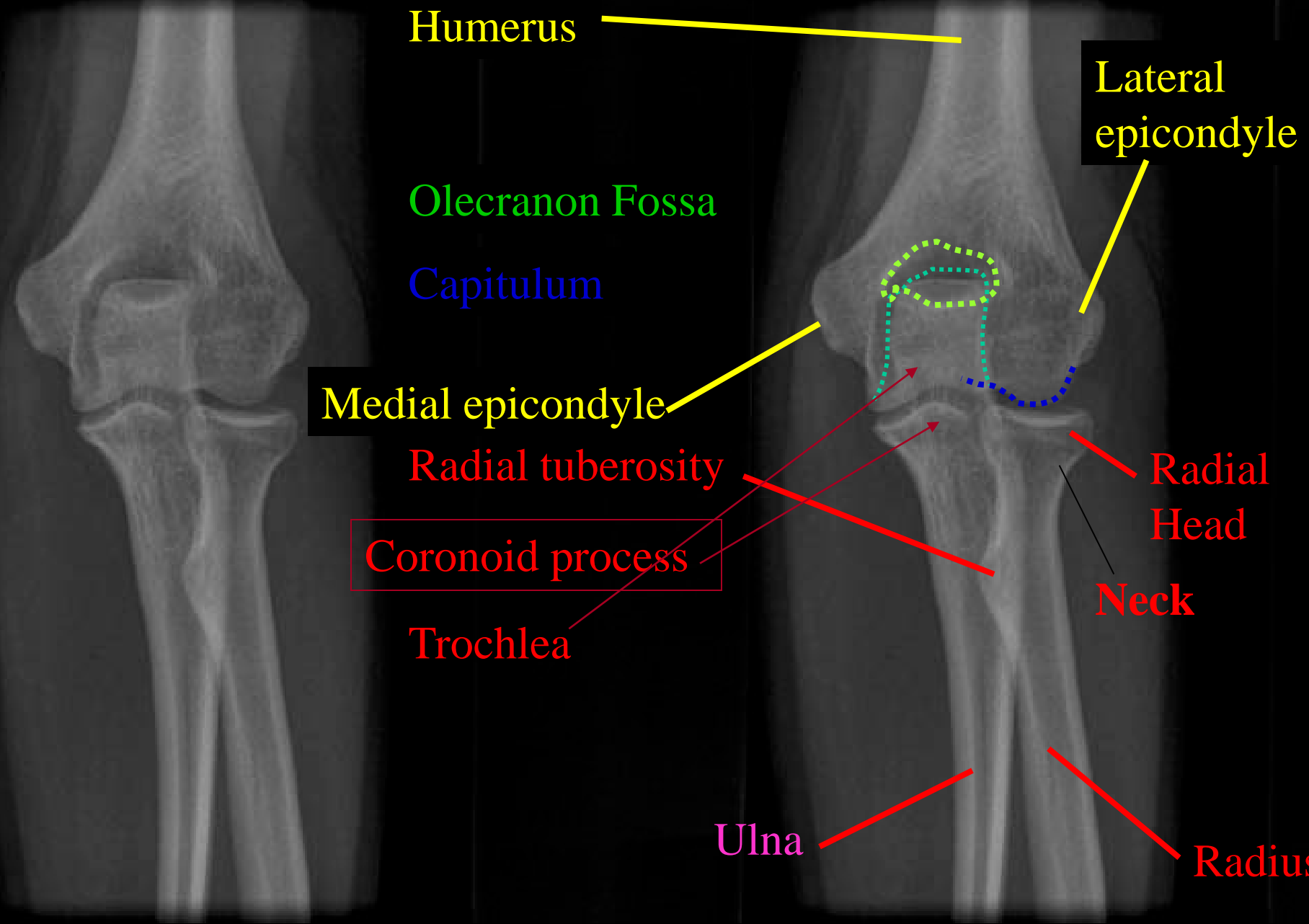
Radial Head

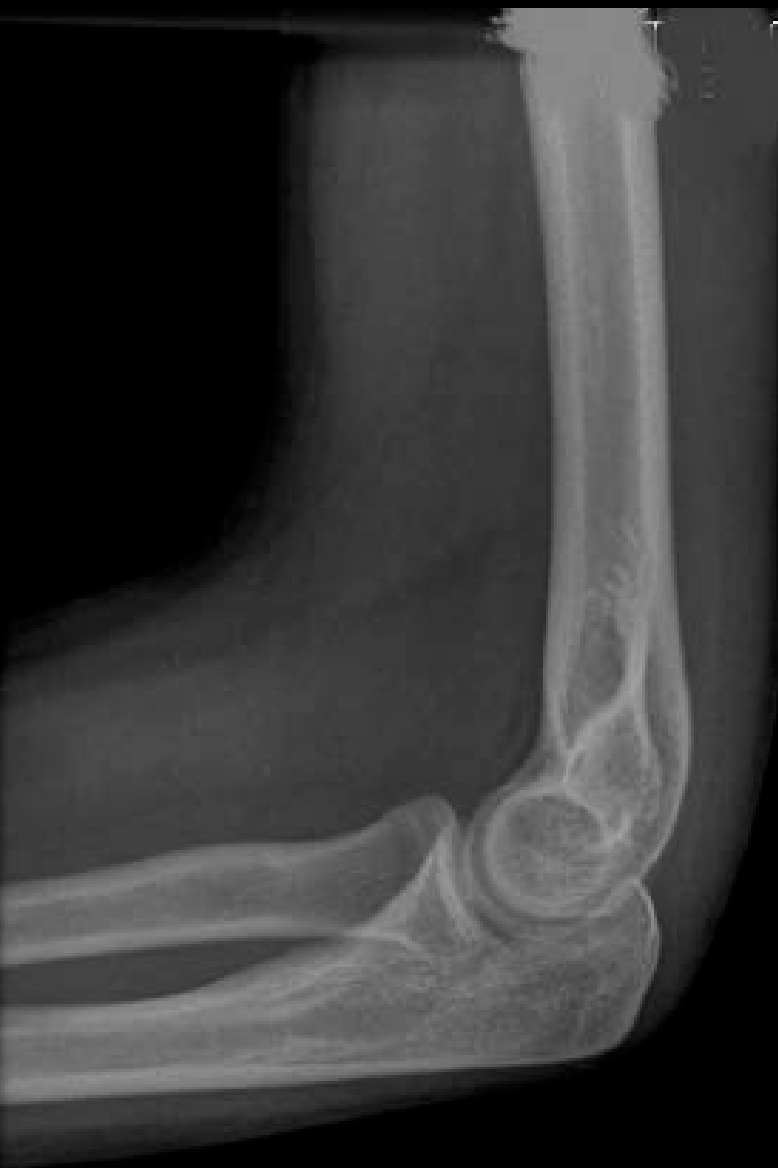Neck

Ulna


Radius

RIGHT ELBOW AP





Humerus





Olecranon Fossa

Radial fossa

Radial tuberosity

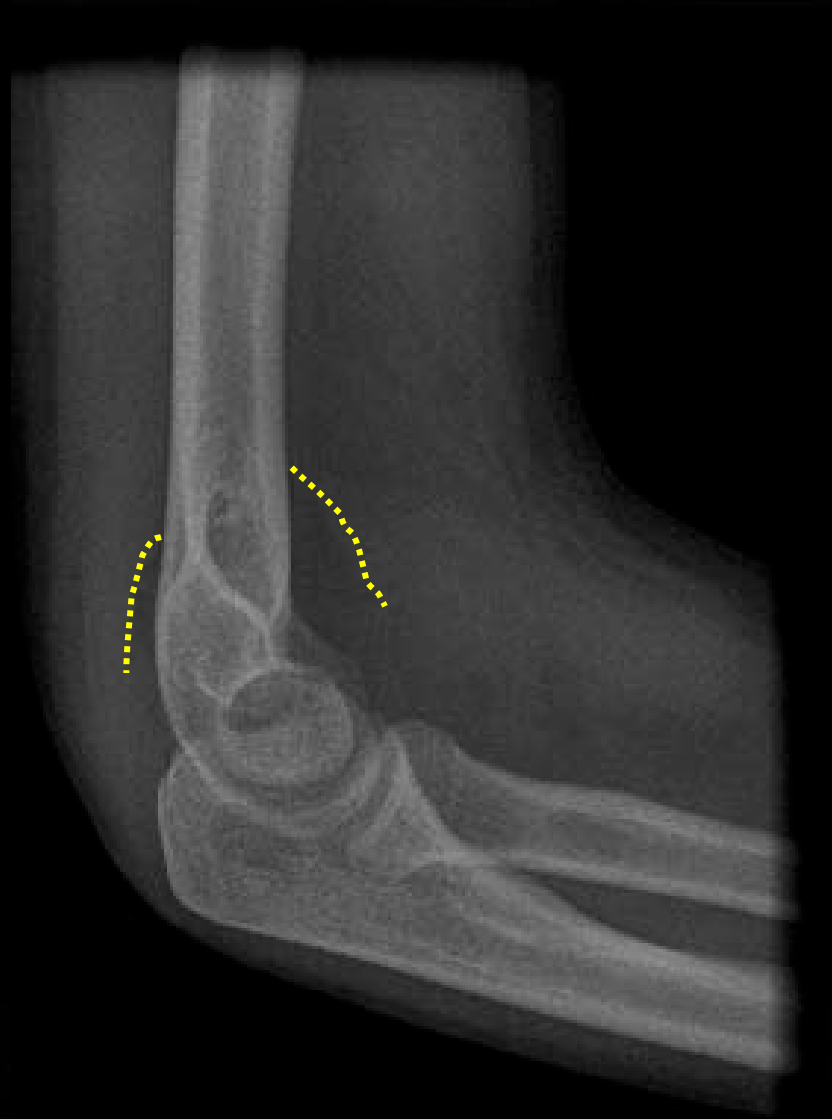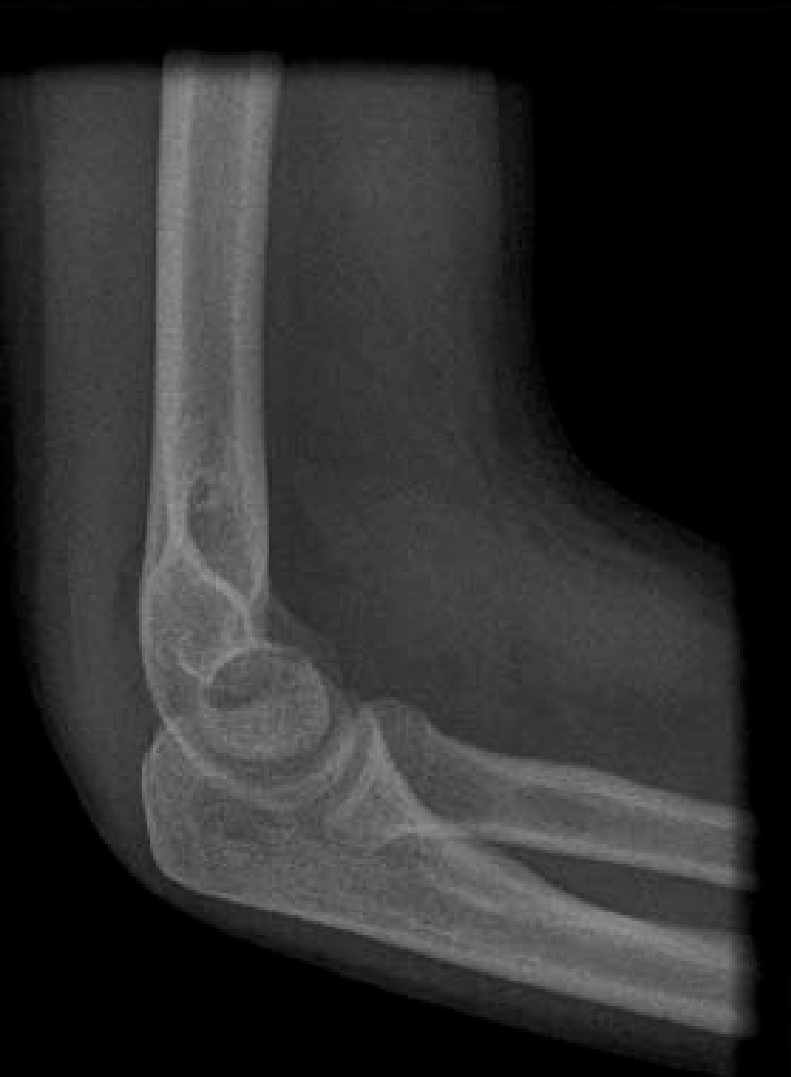Radius



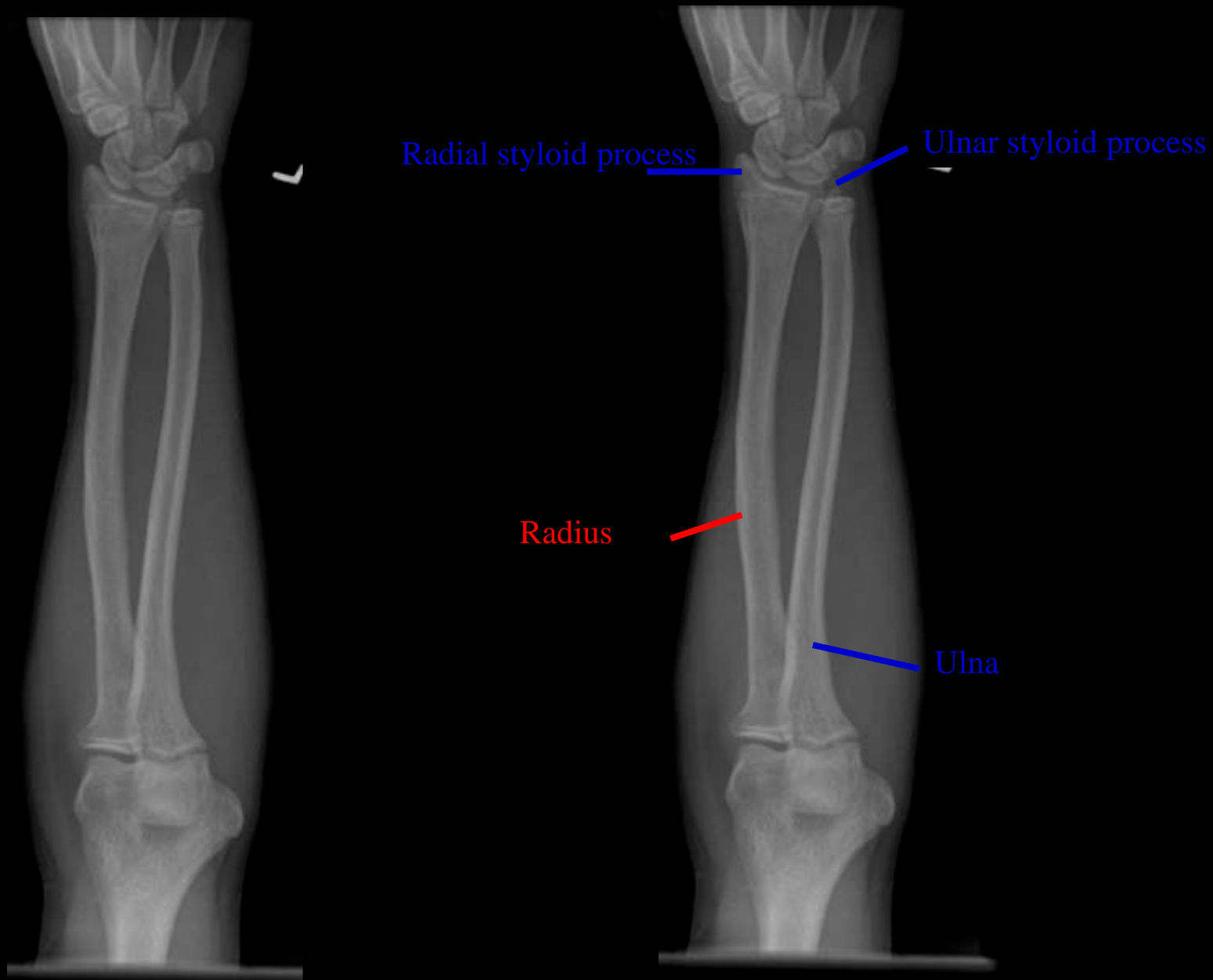
Olecranon



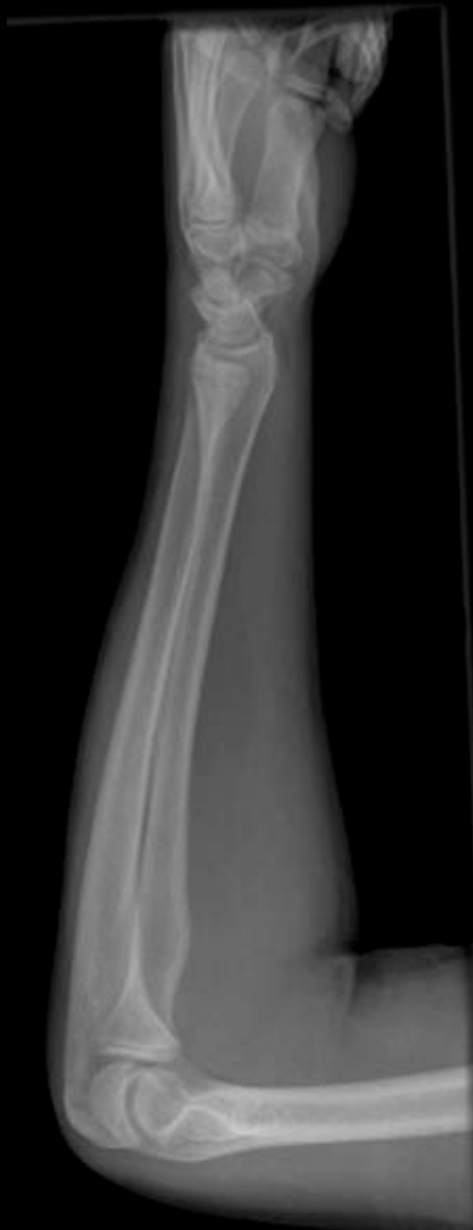RIGHT ELBOW Lat



RIGHT ELBOW LAT- identify joint effusion



LEFT RADIUS & ULNA – FOREARM AP



Ulnar styloid process



Radial styloid process



Ulna



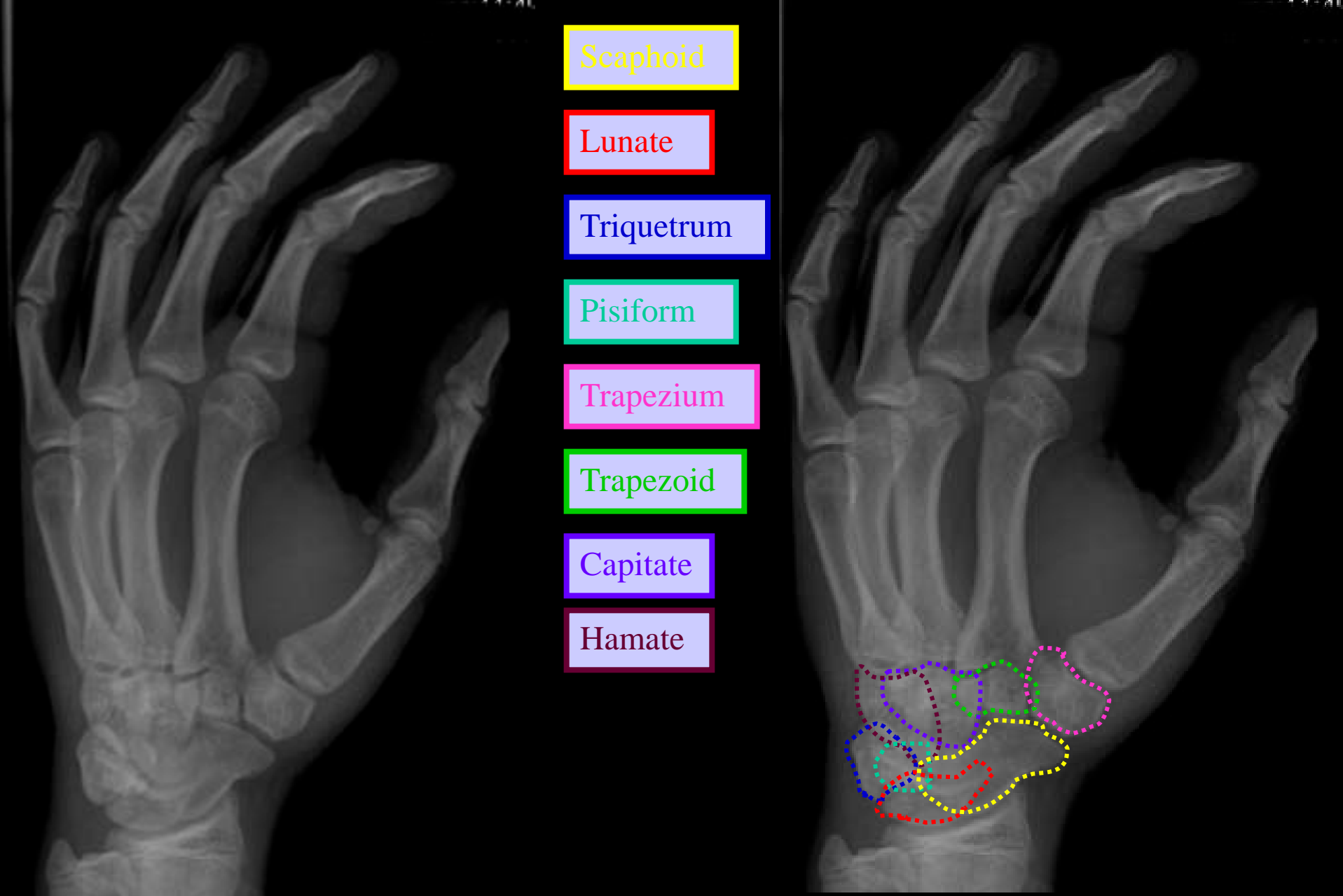
Radius



Humerus



Radius & Ulna Lateral



Scaphoid

Lunate

Triquetrum

Pisiform

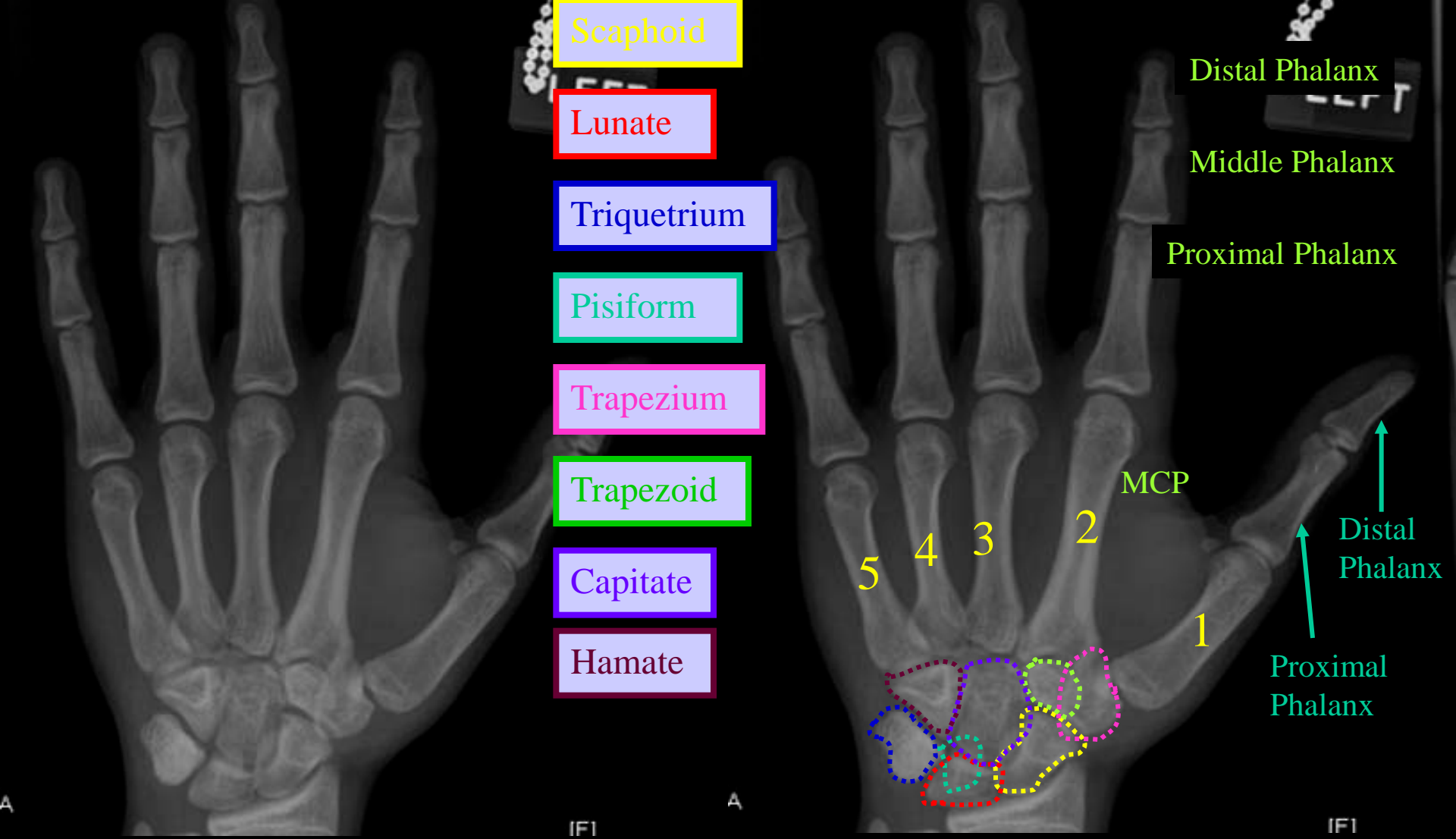
Trapezium

Trapezoid

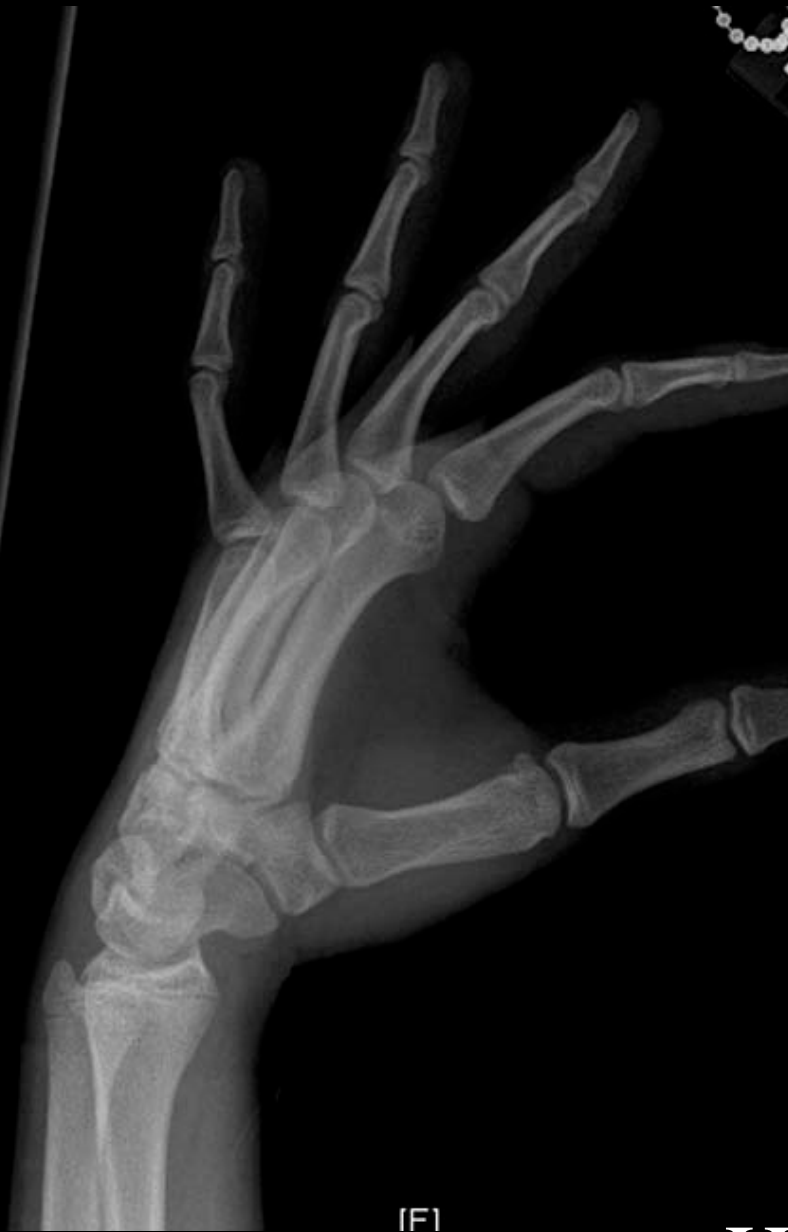Capitate

Hamate

Hand Oblique



Hand PA View



Scaphoid

Lunate

Triquetrum

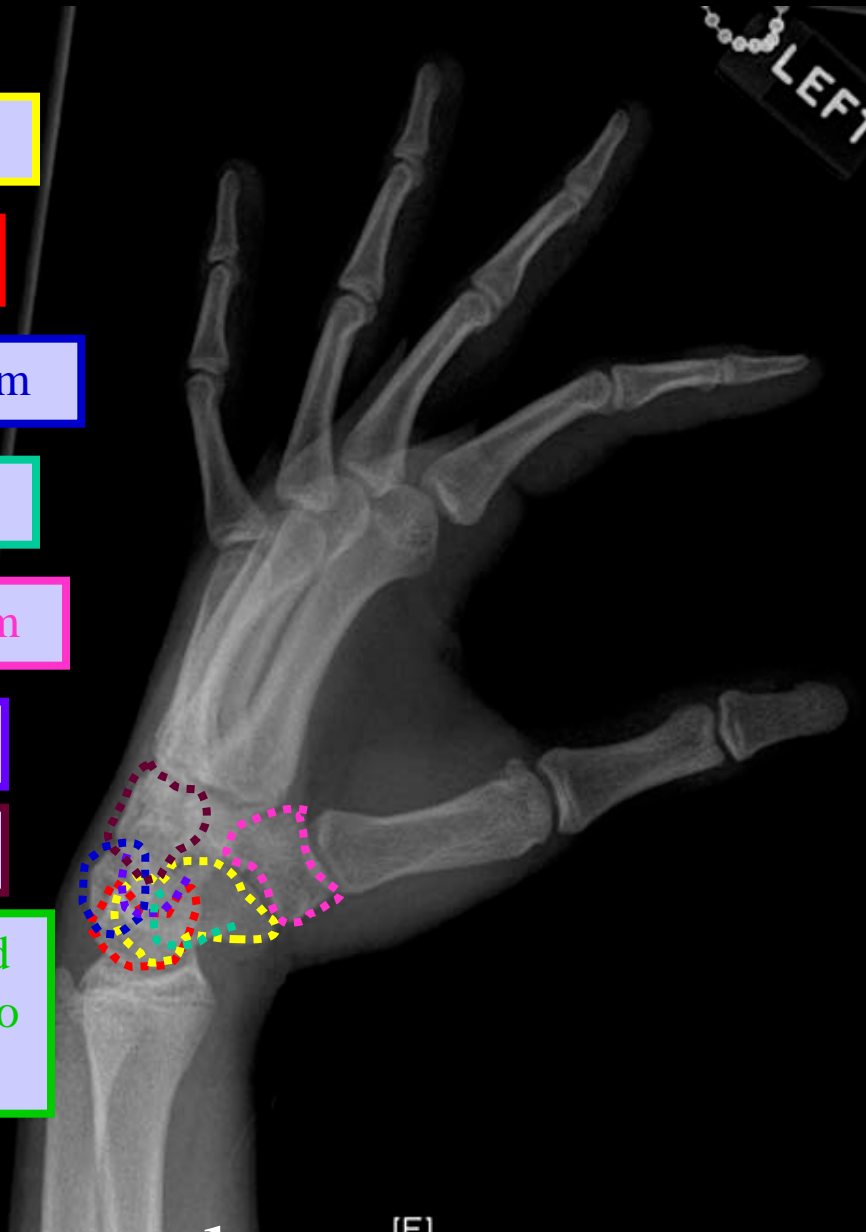
Pisiform

Trapezium

Capitate

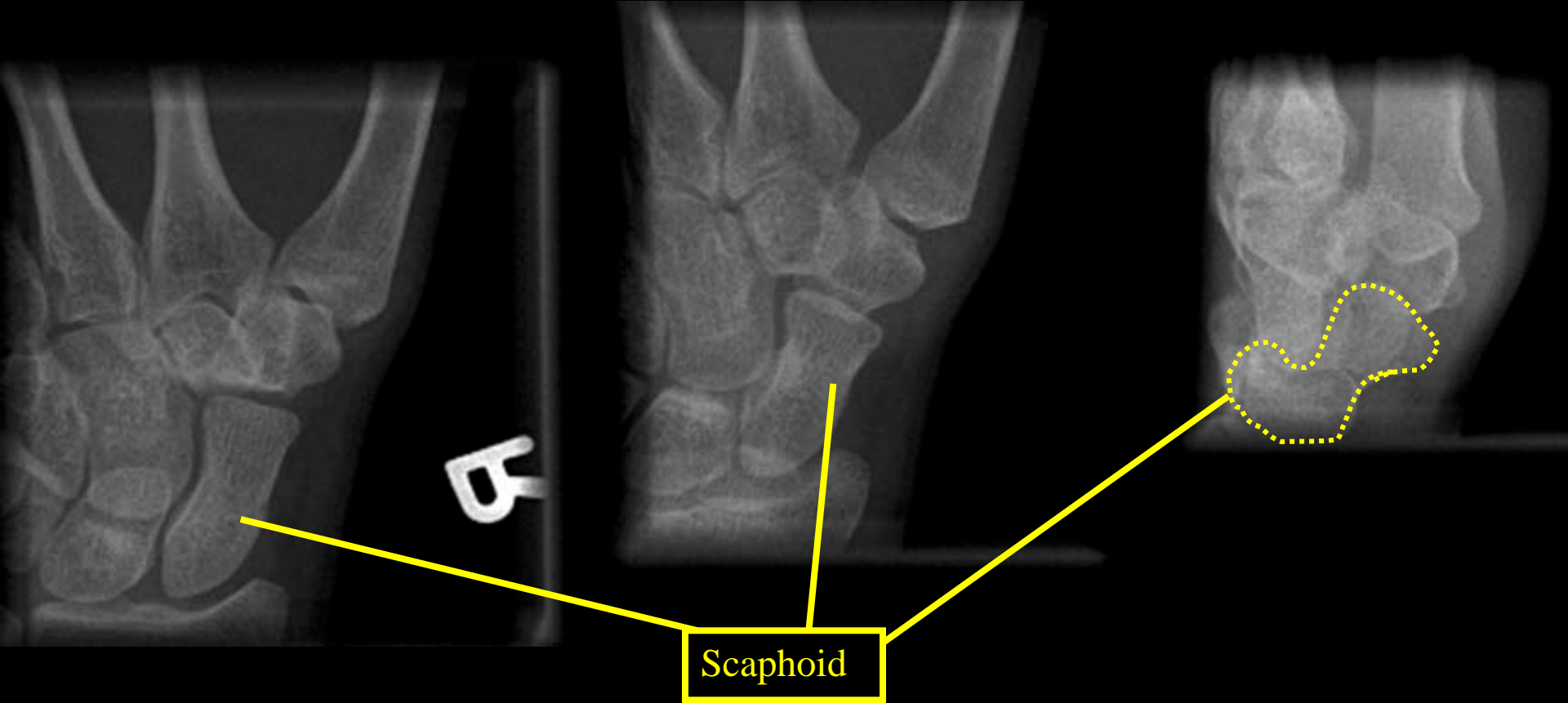
Hamate

Trapezoid
difficult to
view



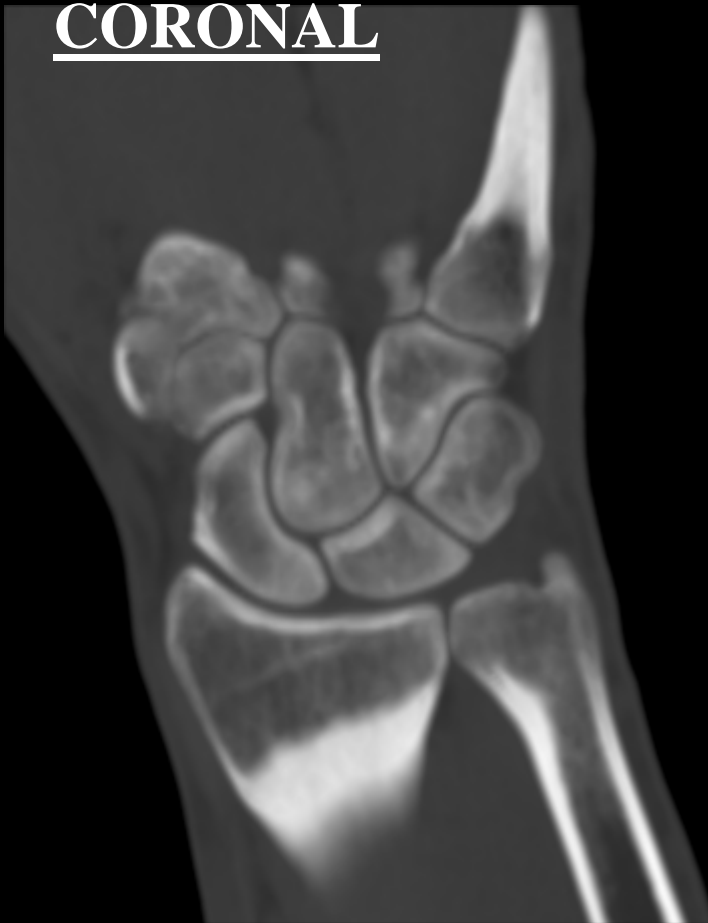Hand Lateral

Scaphoid



CT WRIST

CORONAL

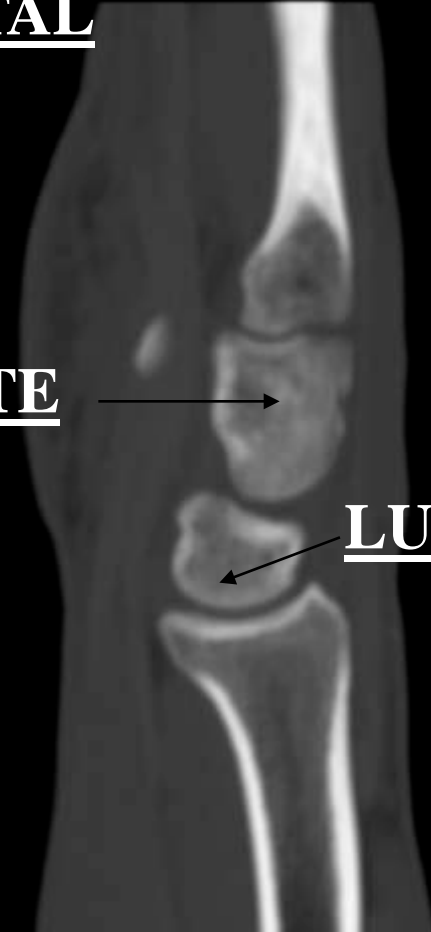


SAGITTAL

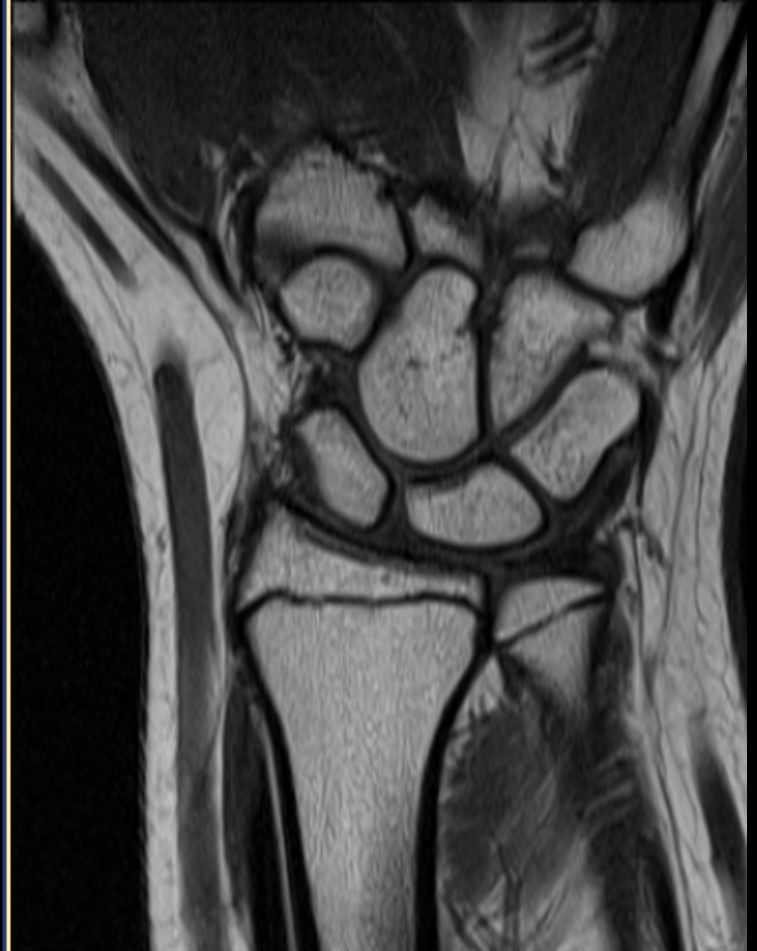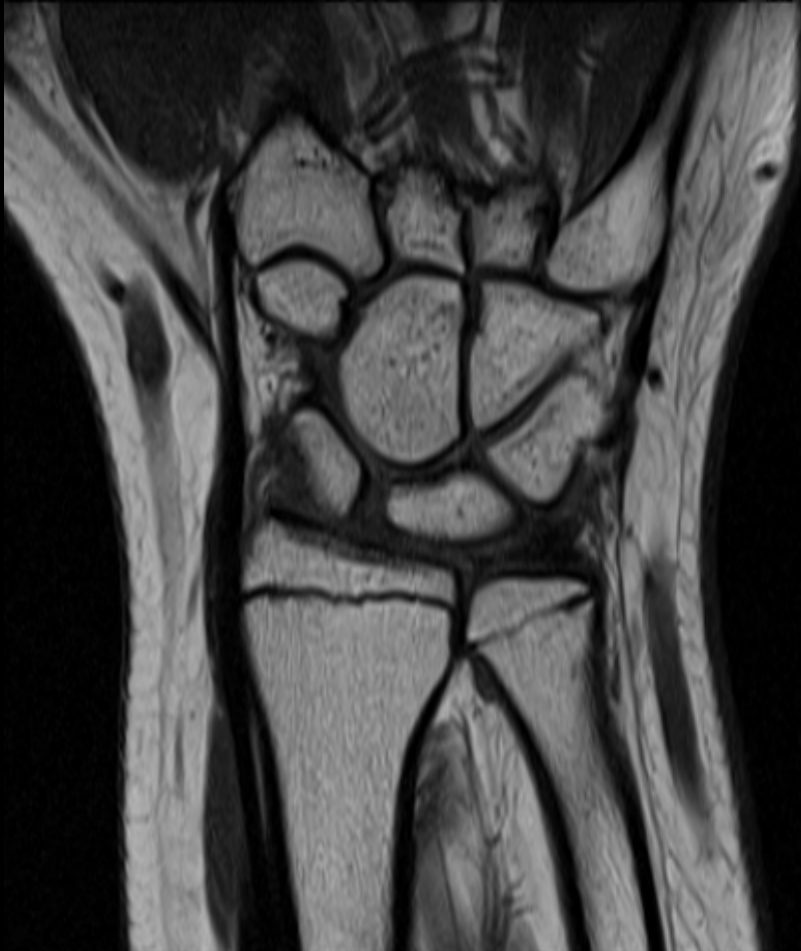CAPITATE



LUNATE

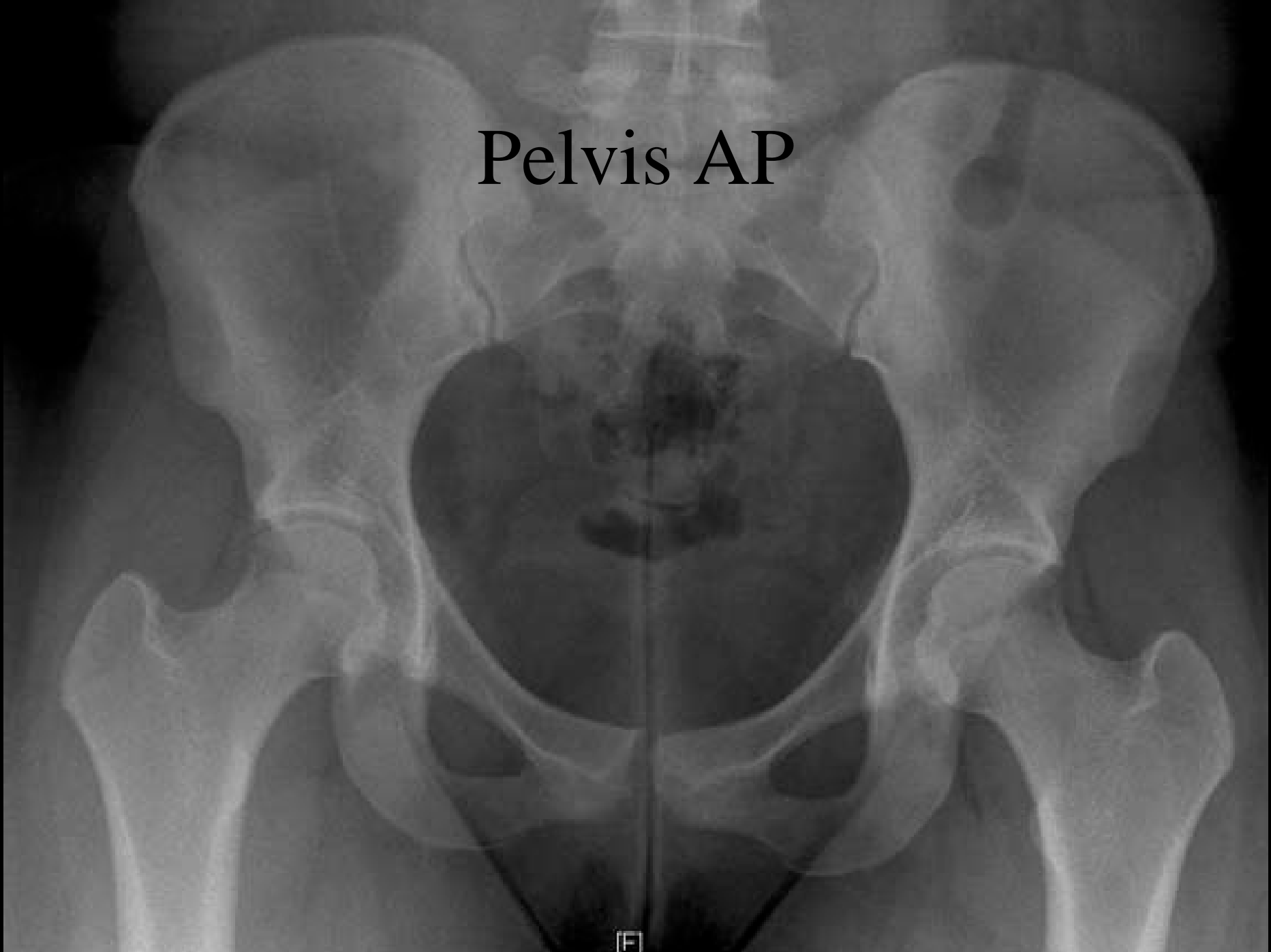


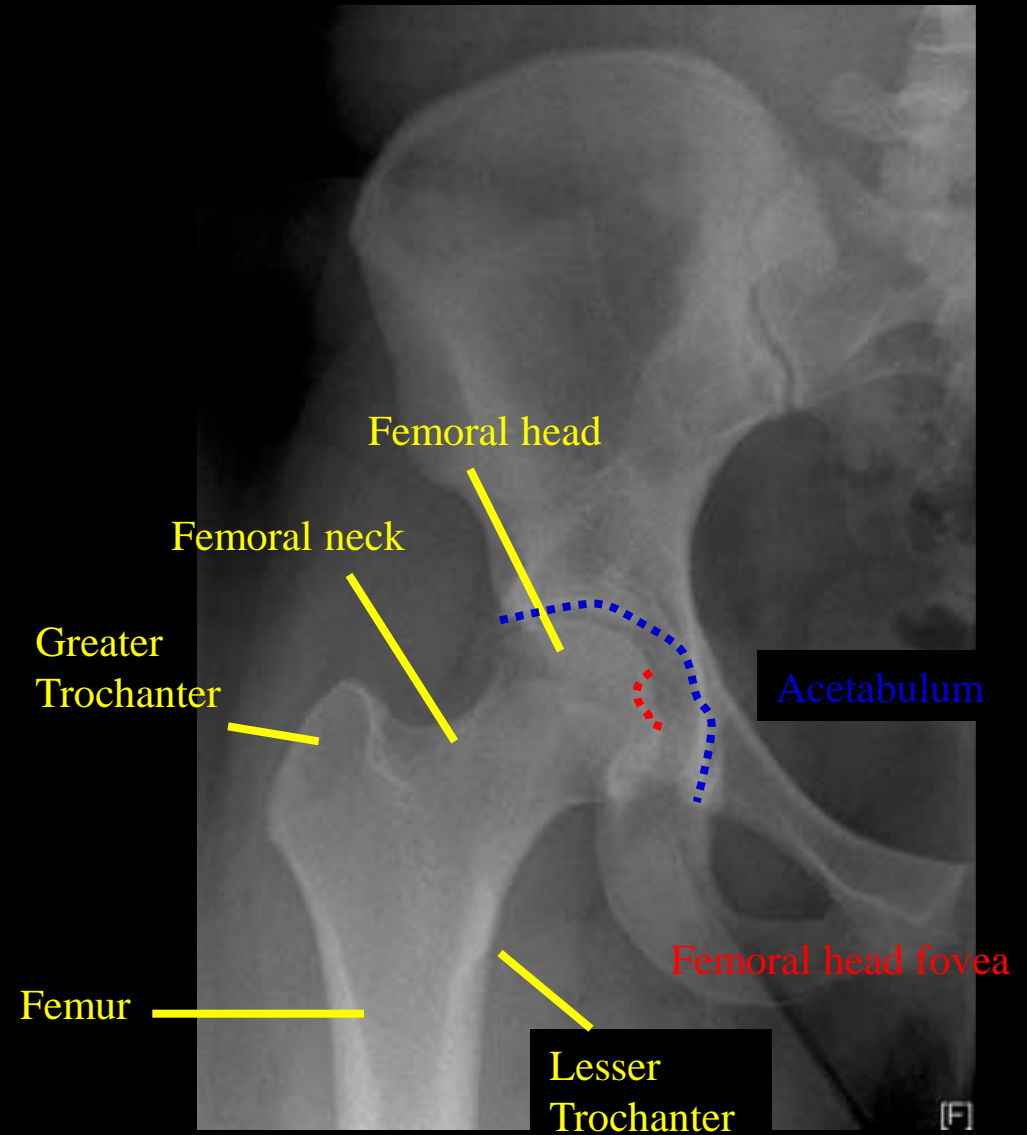
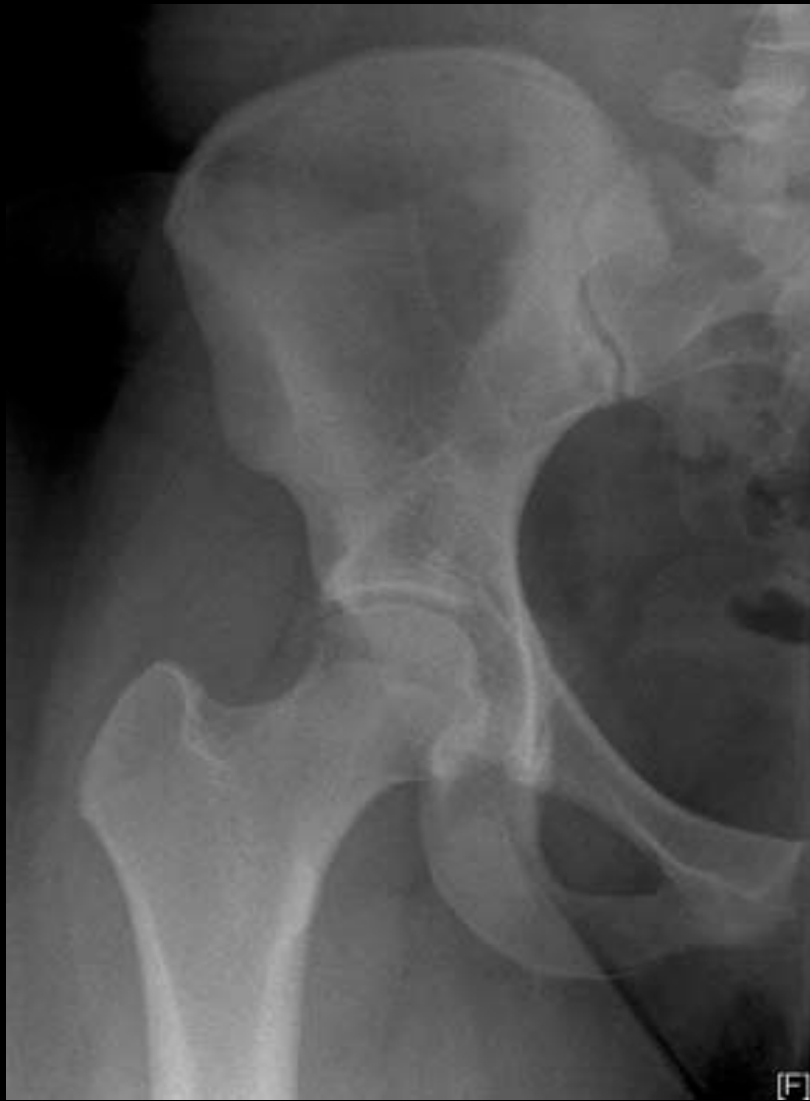MRI WRIST



Pelvis AP

[F]

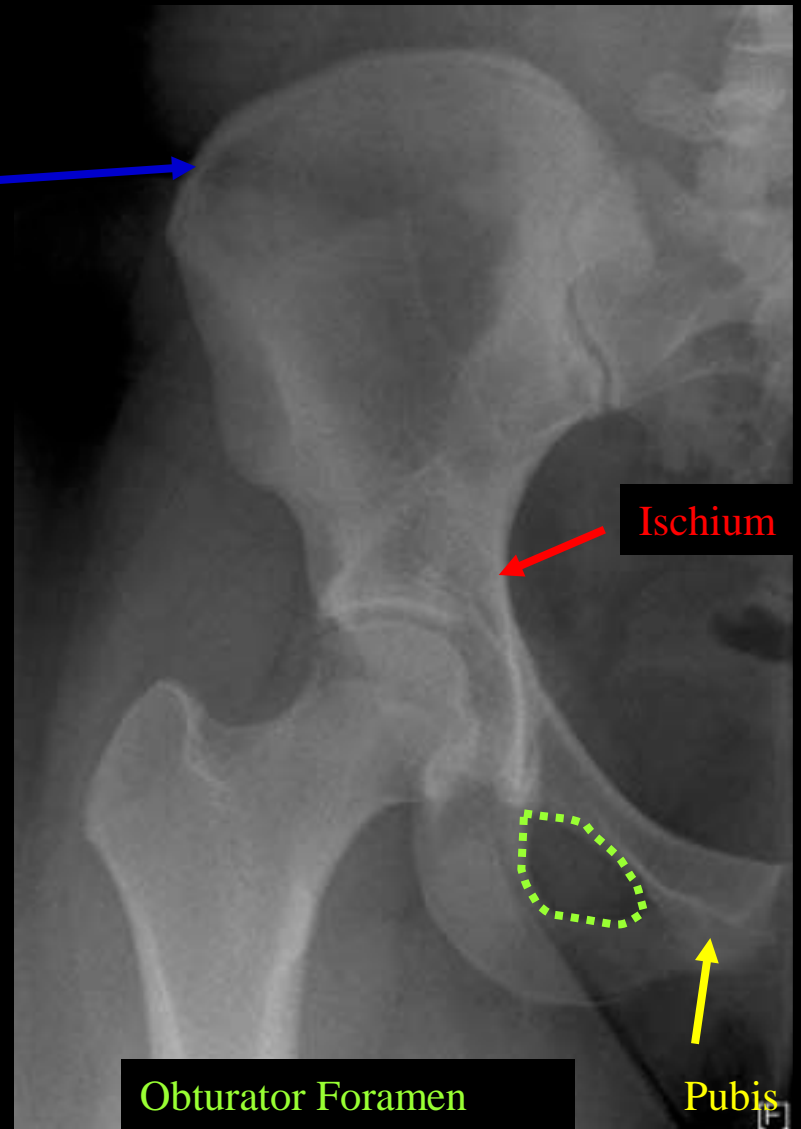




Pelvis AP (Femur)



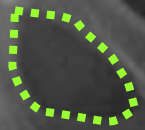
Iliac



Ischium

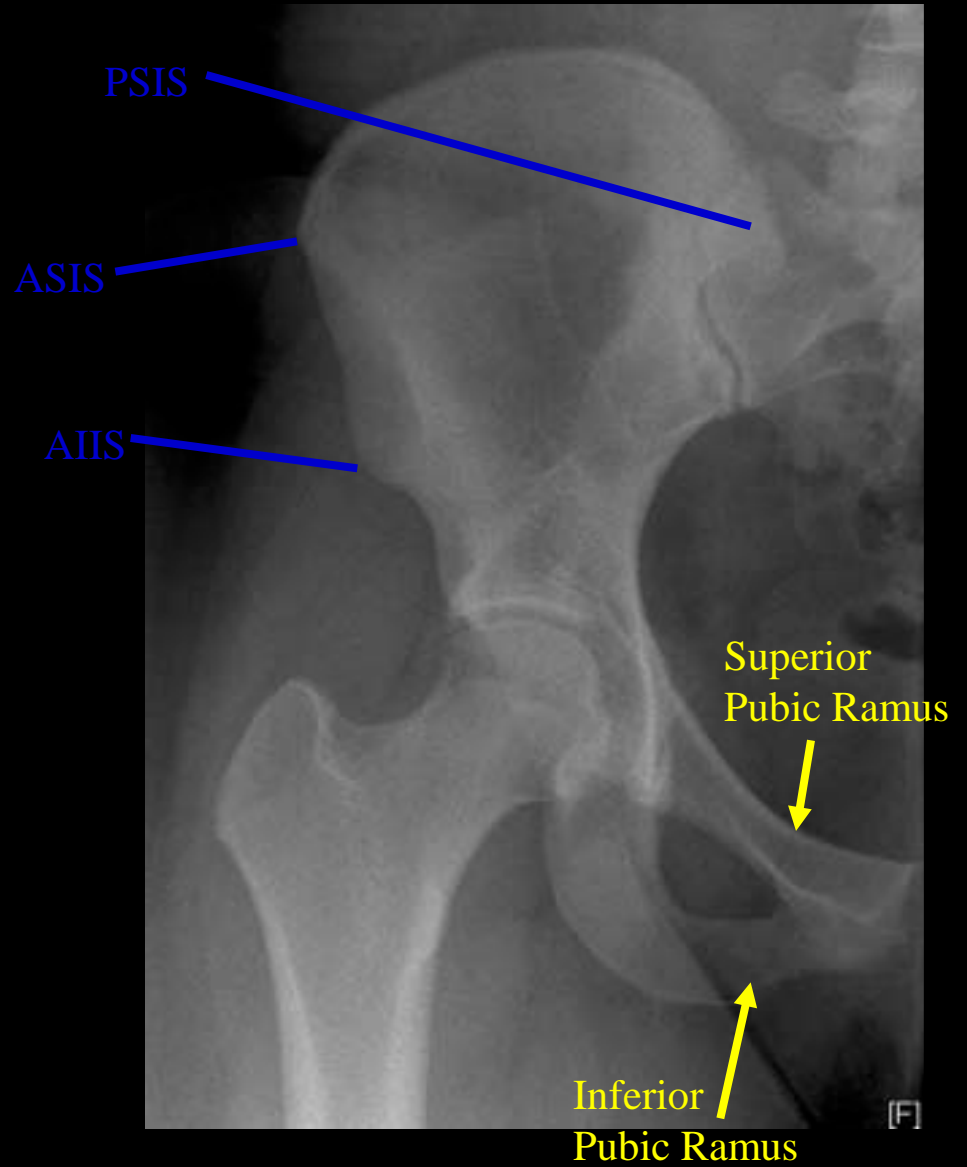
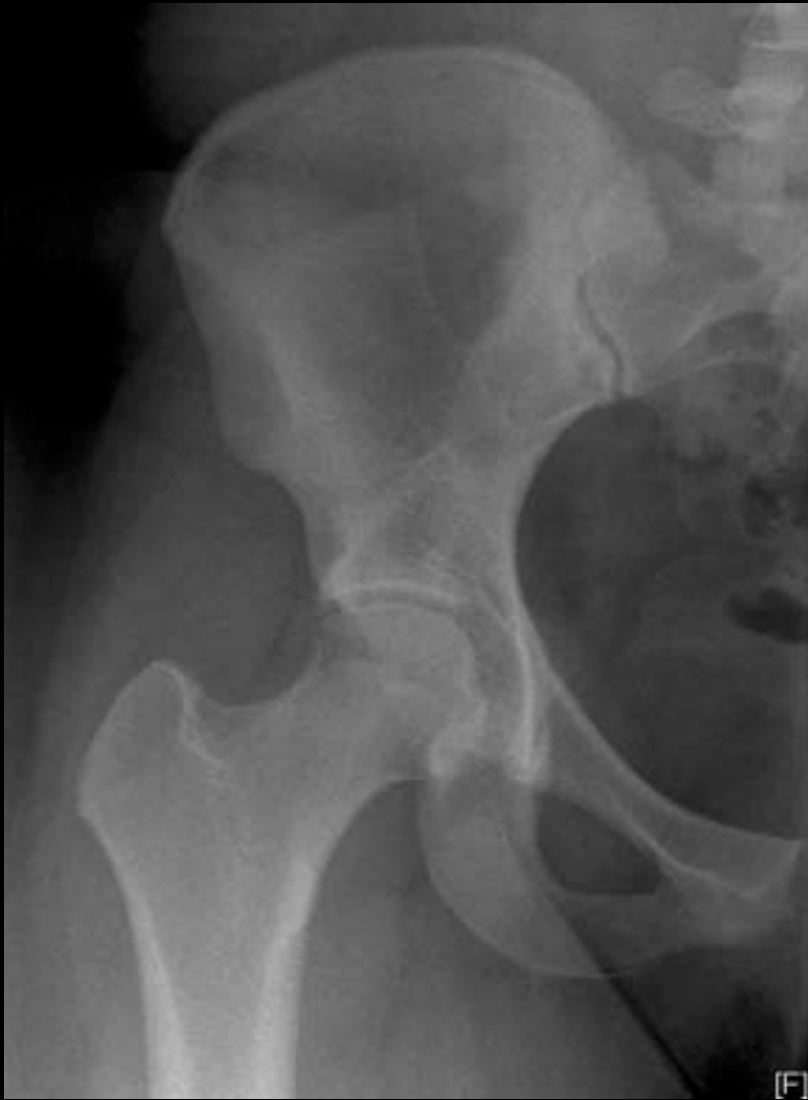

Obturator Foramen

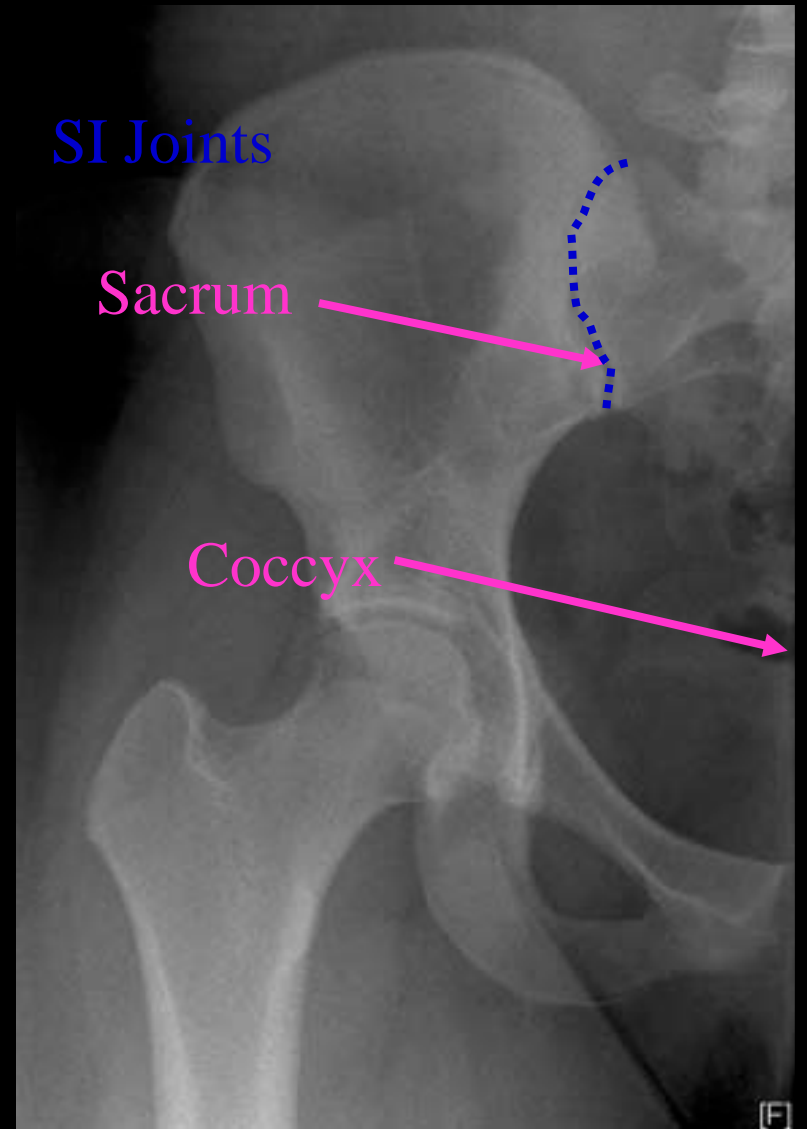


Pubis

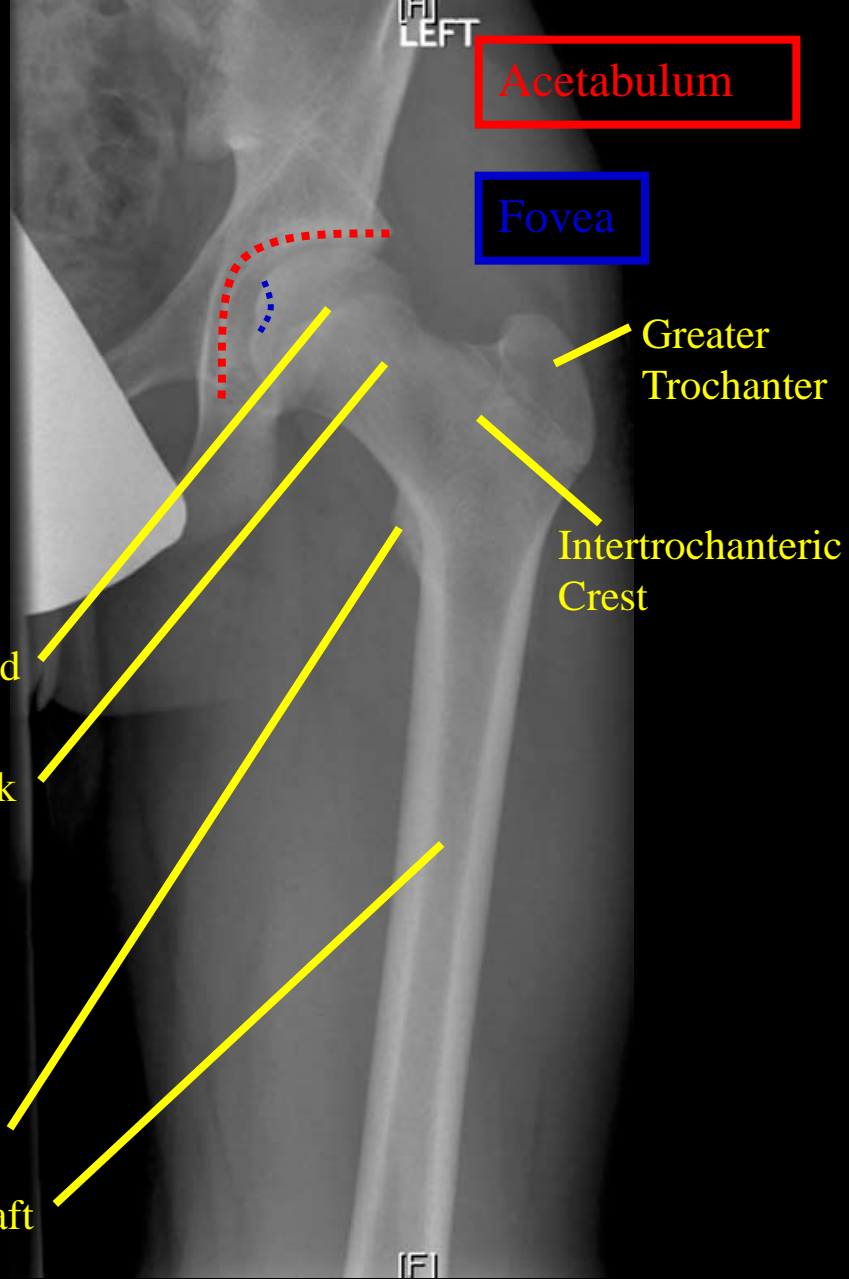
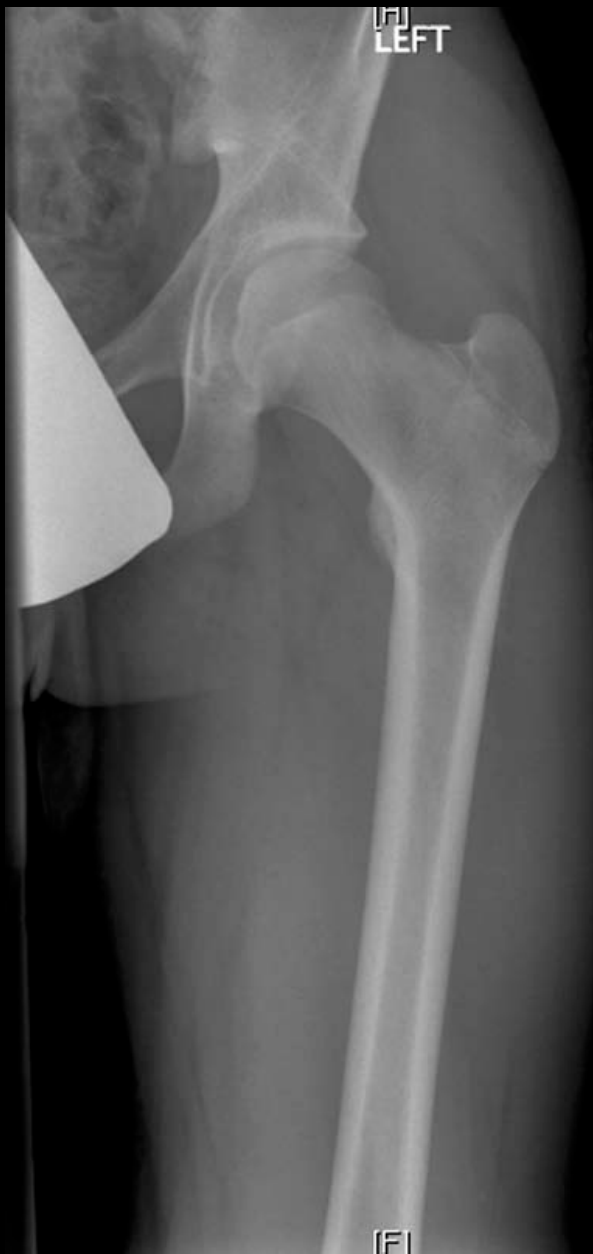Pelvis AP (Hip)



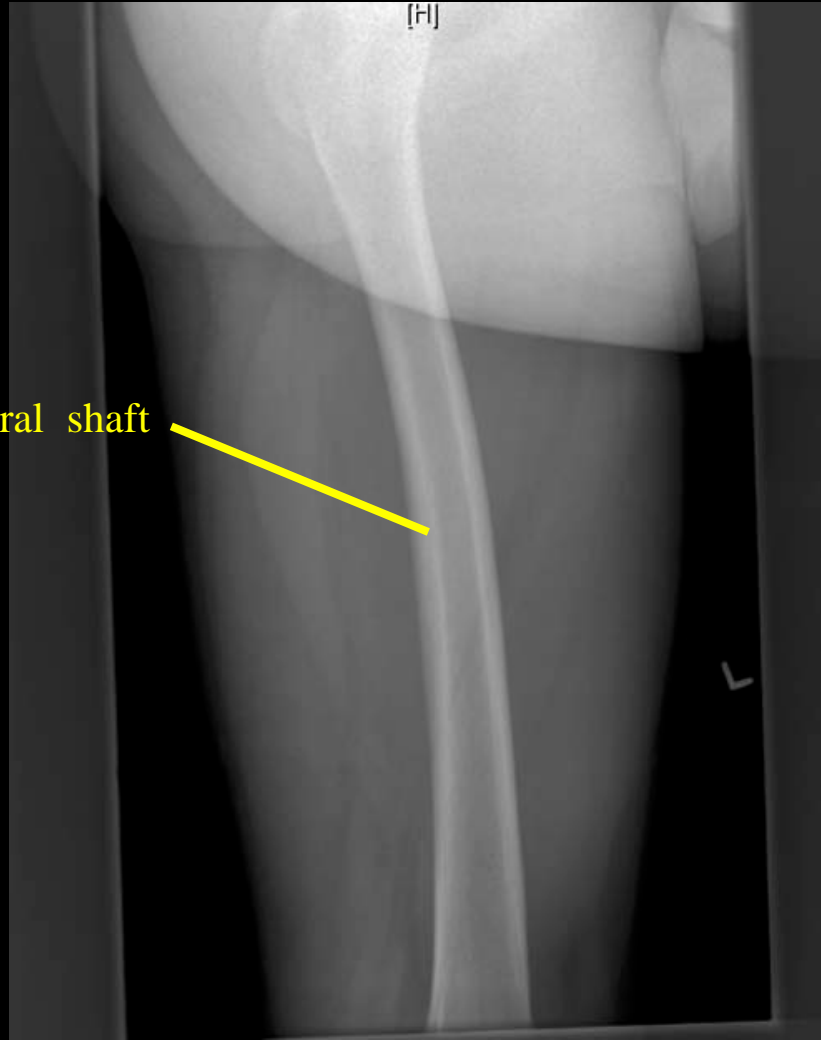
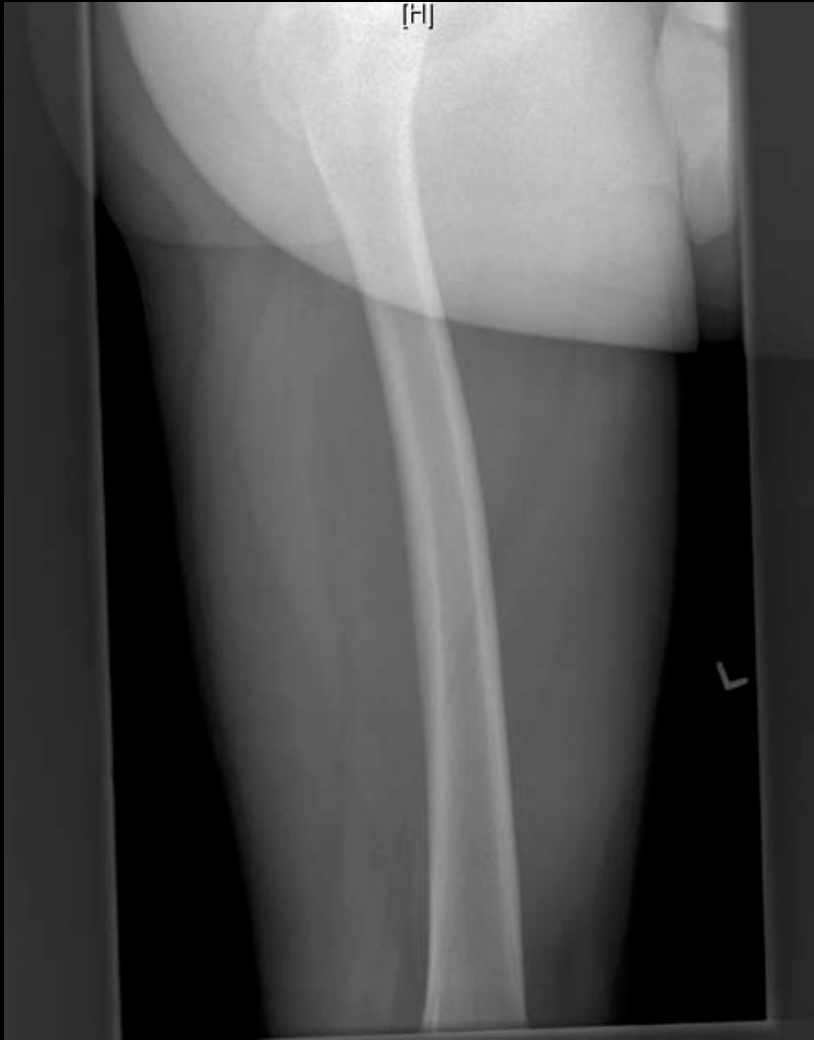Pelvis AP



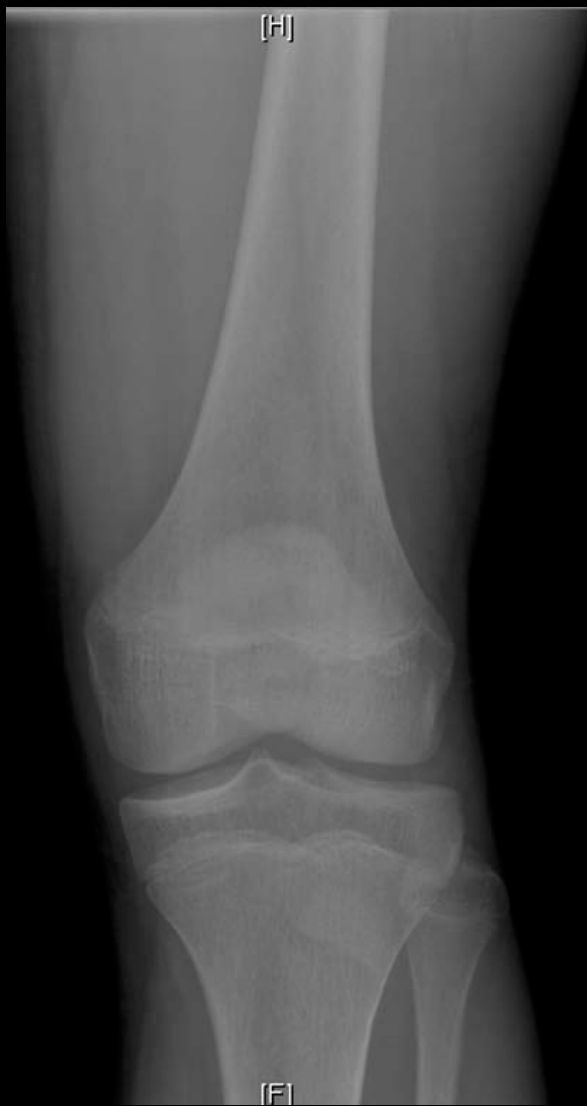Pelvis AP (SI Joints)



Femur AP



LEFT FEMUR LAT

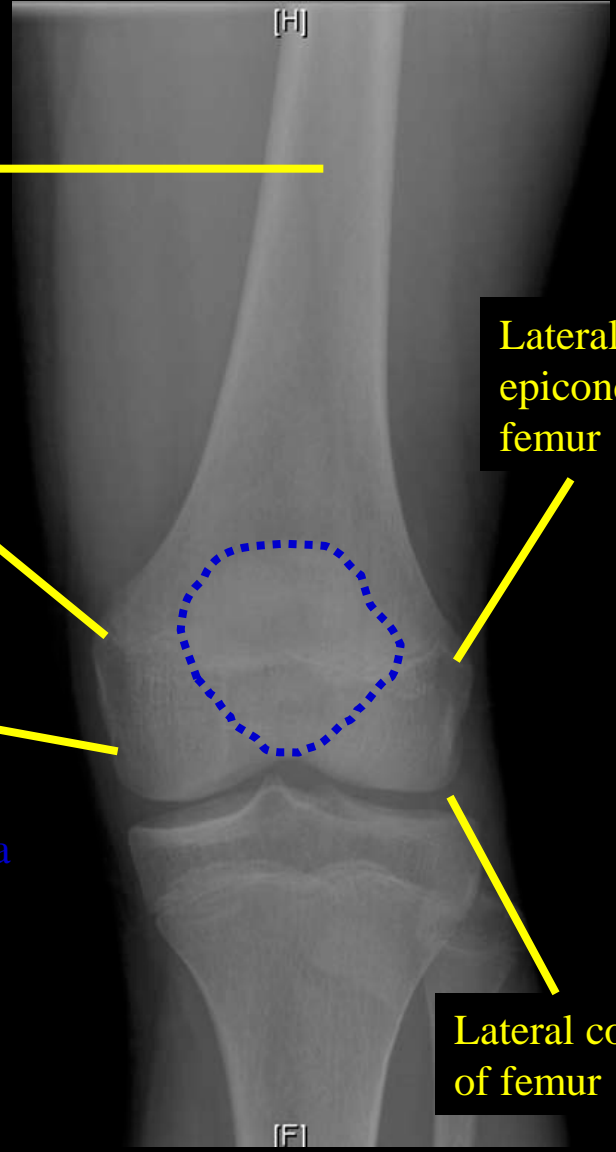


Femoral shaft

Medial epicondyle of femur

Medial condyle of femur

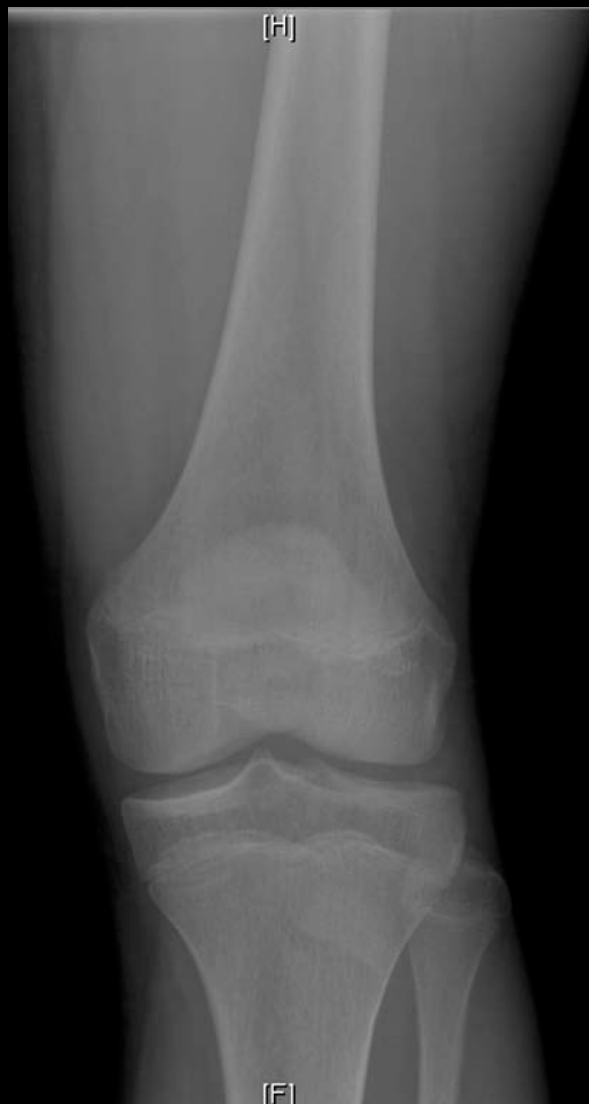Patella



Lateral epicondyle of femur

Lateral condyle of femur

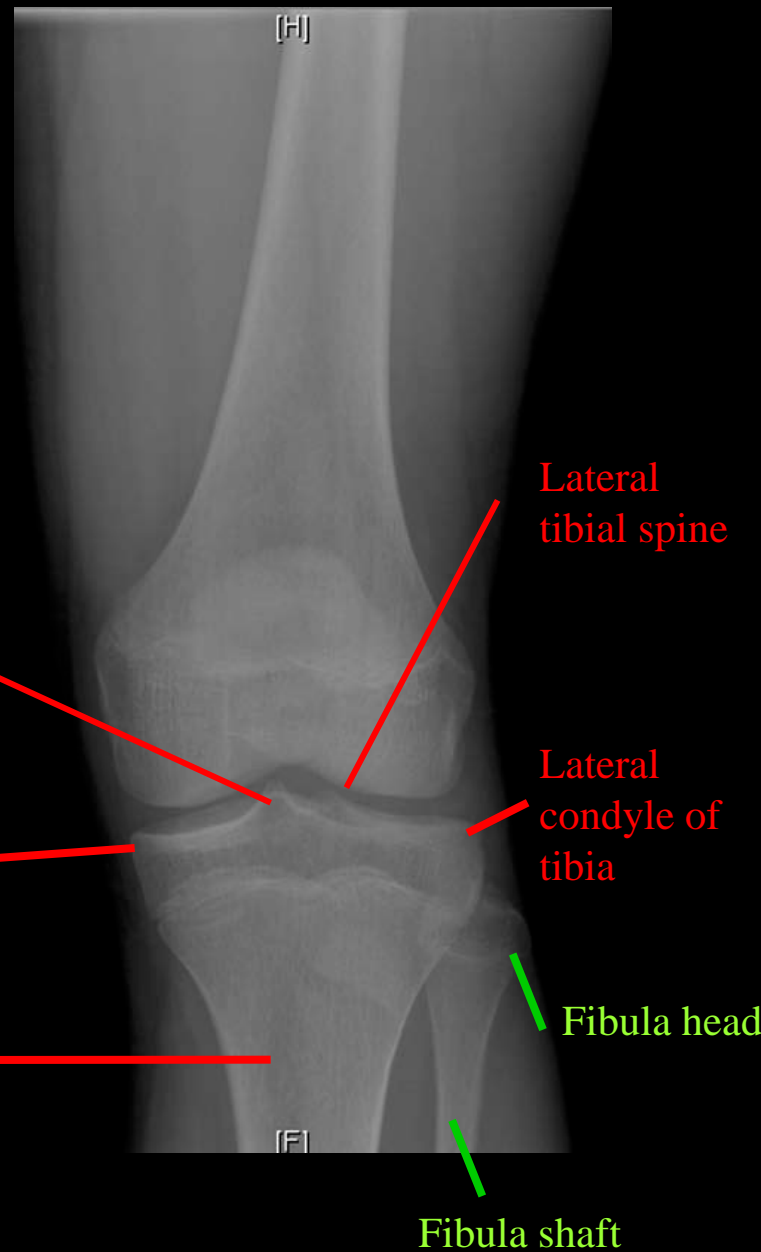
Knee AP (Femur)



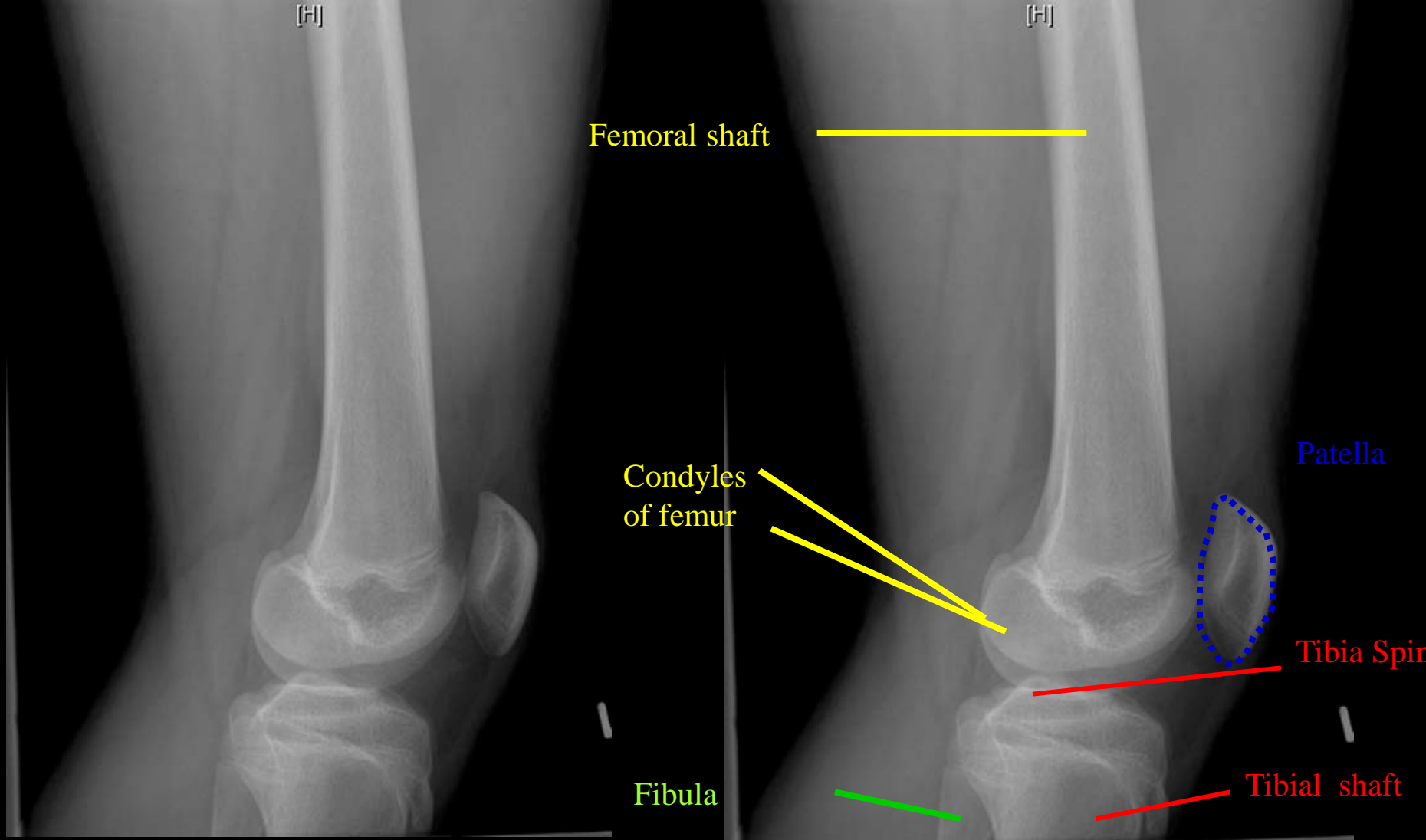
Medial tibial spine

Medial condyle of tibia

Tibial shaft

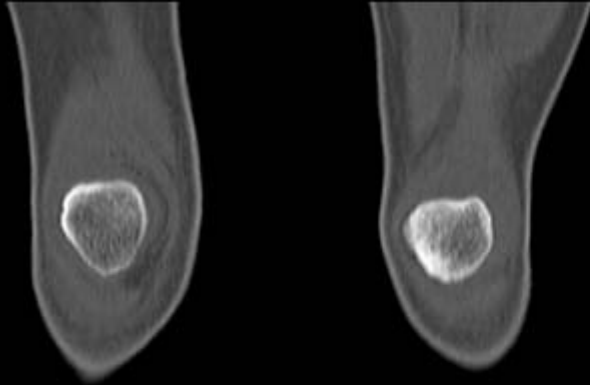


Knee AP (Tibia/Fibula)

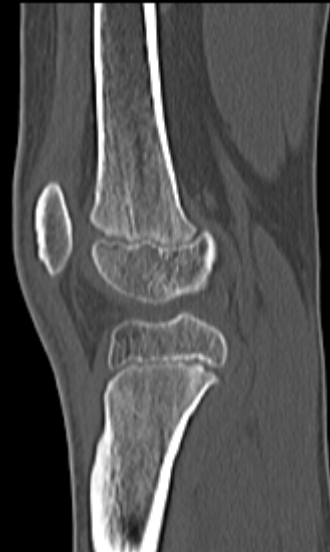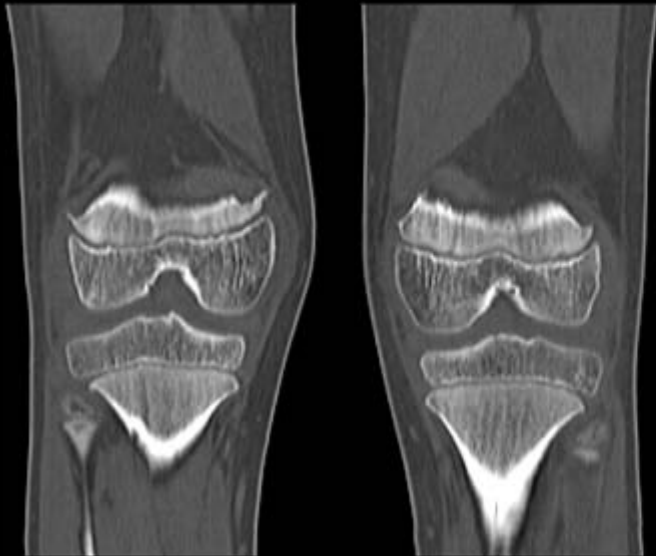
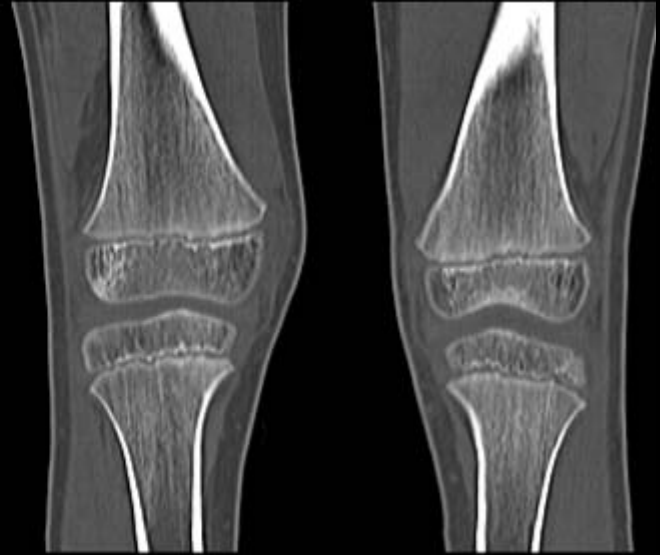


Knee Lat

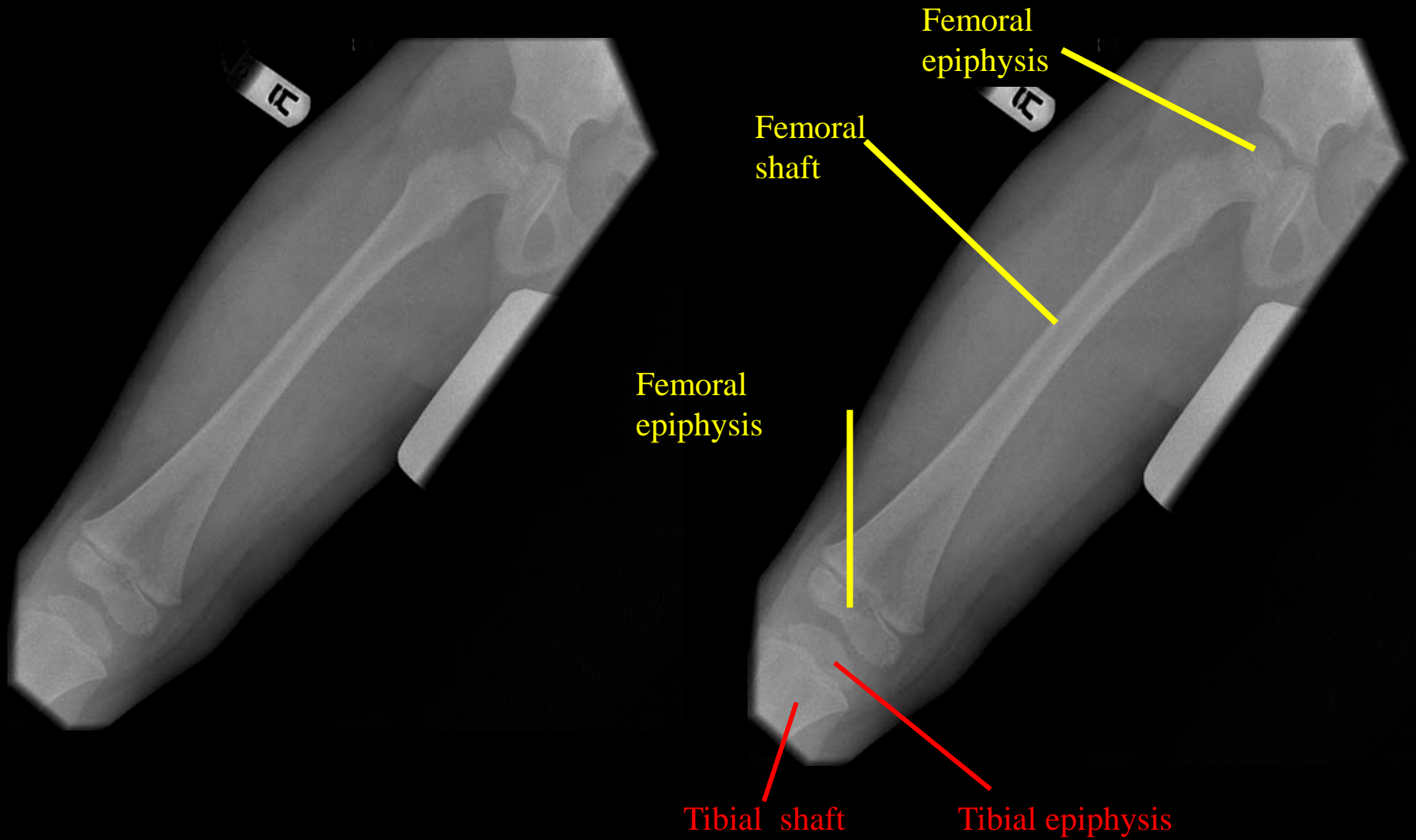
MRI Knee/Patella



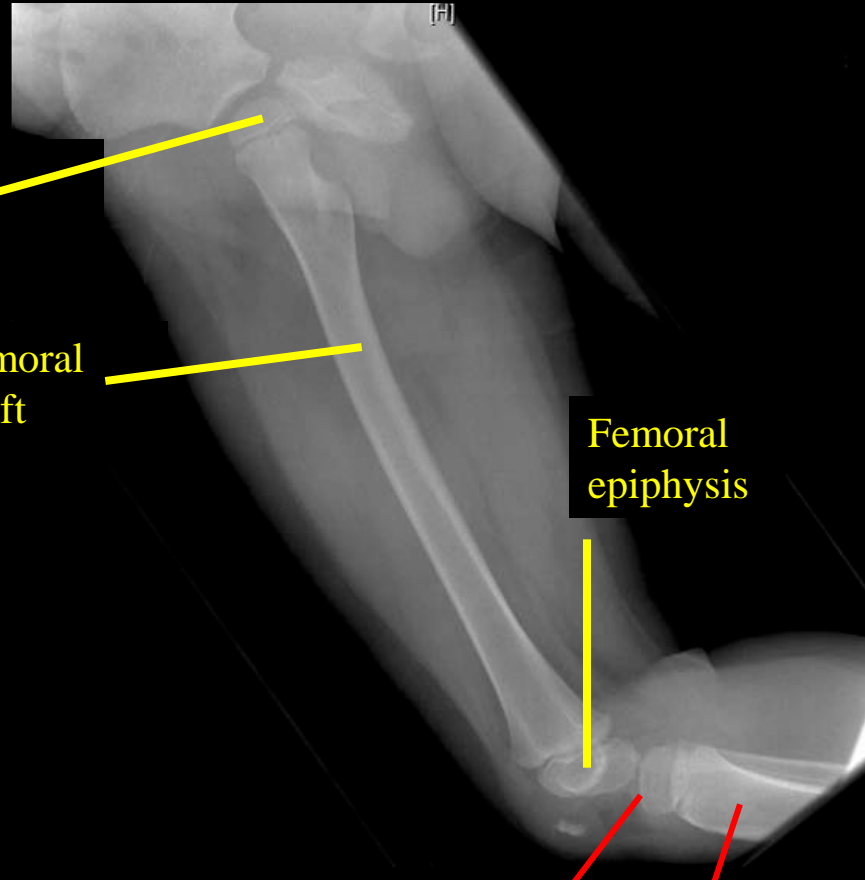
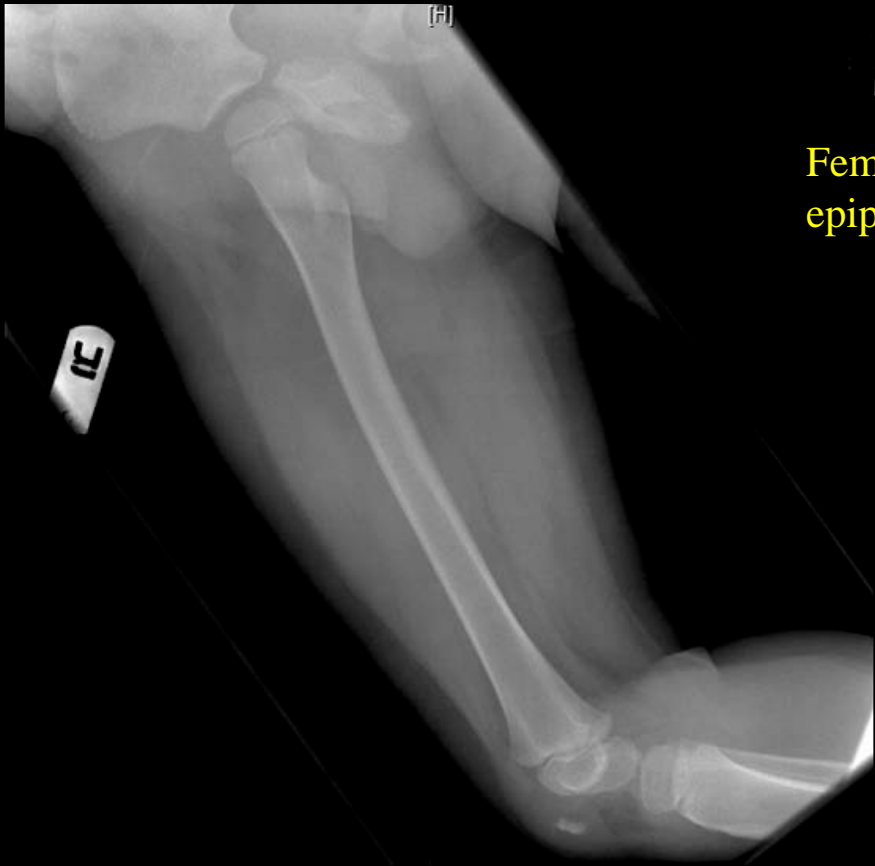
Patellae



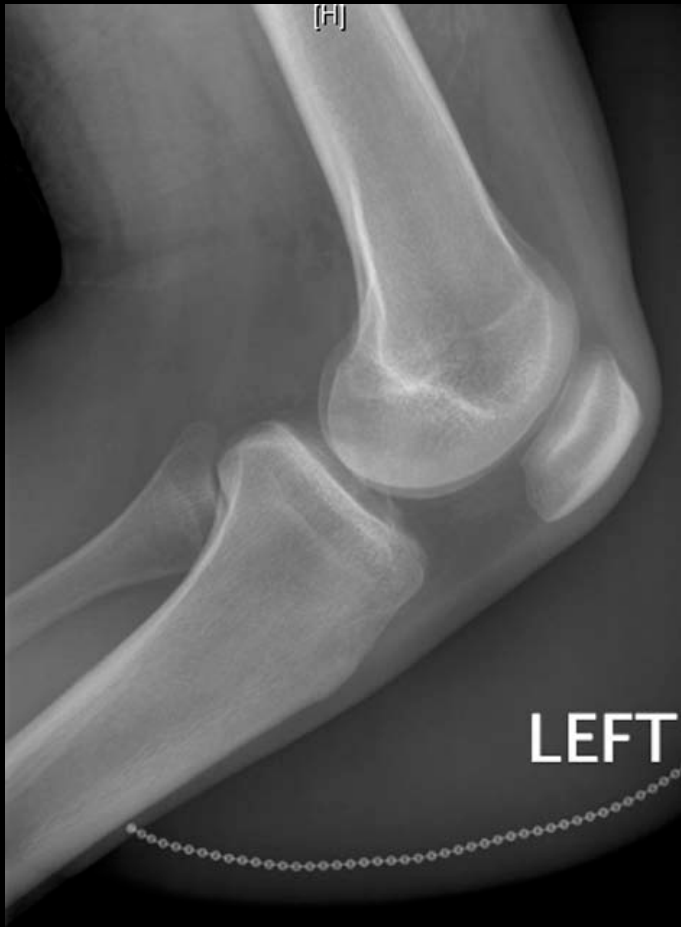Sagittal Knee



Pediatric Femur AP (Epiphysis)



Pediatric Femur Lat

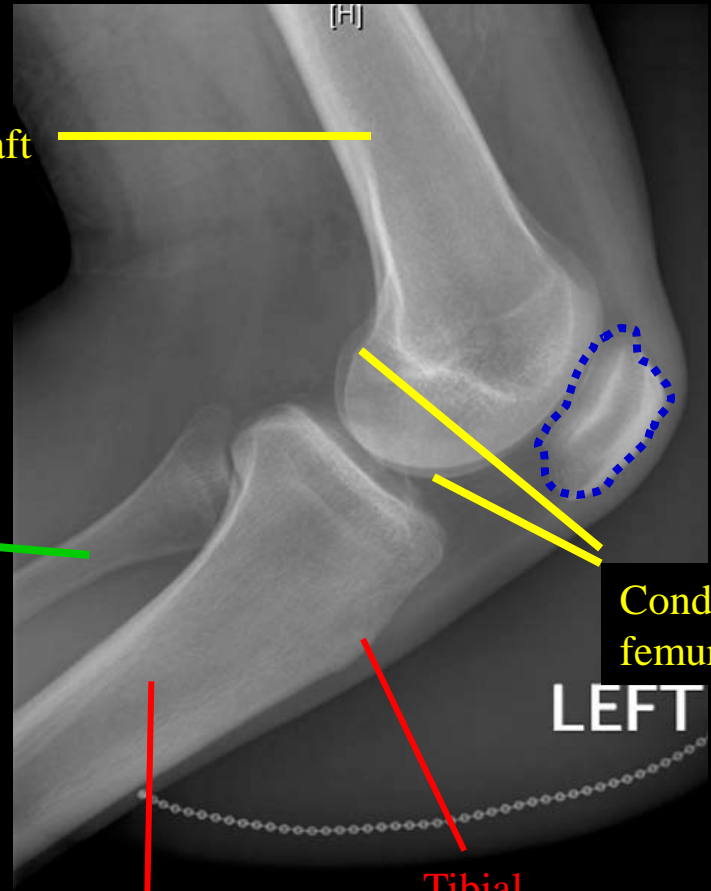


Femoral shaft

Fibula

Tibial shaft

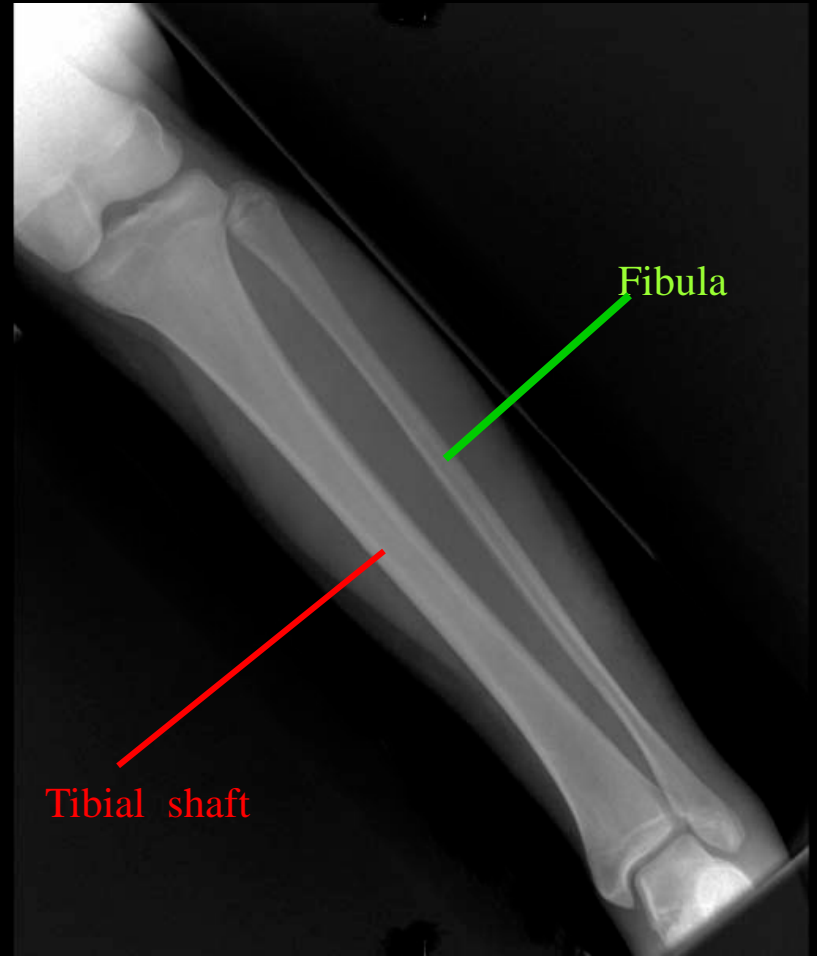
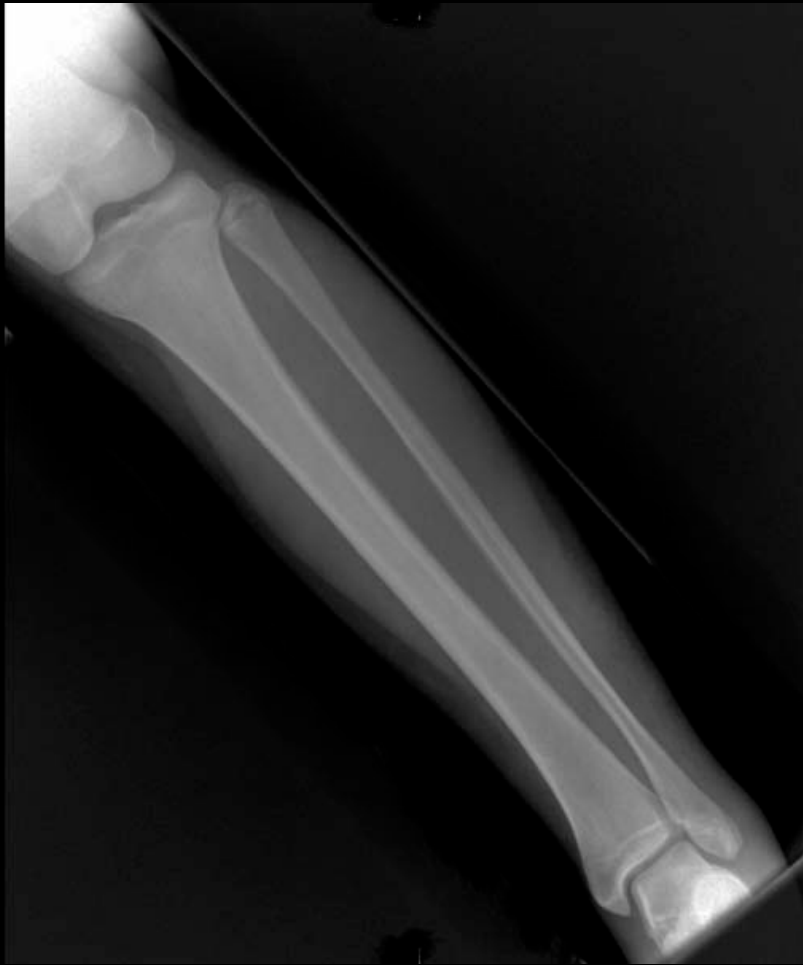Tibial tuberosity



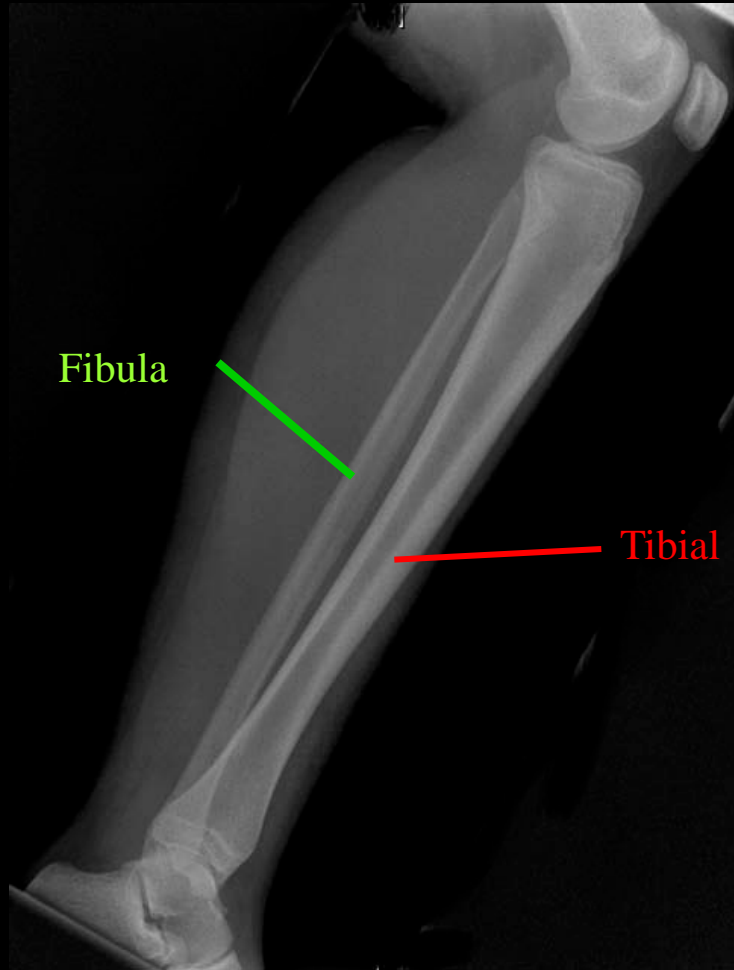
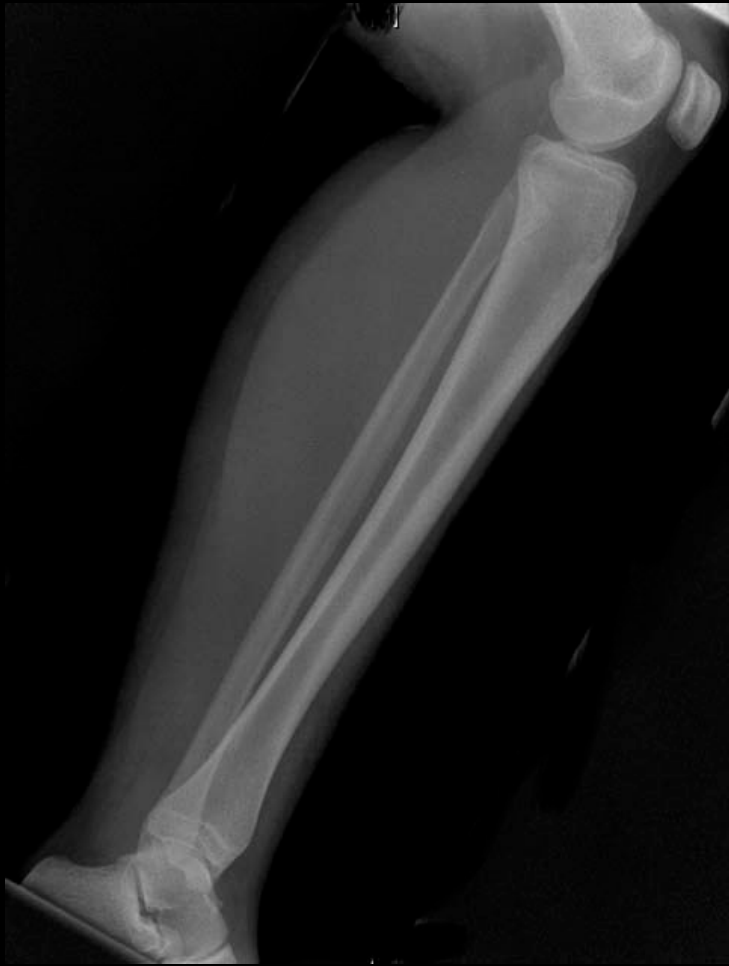Patella

Condyles femur

Knee Lat

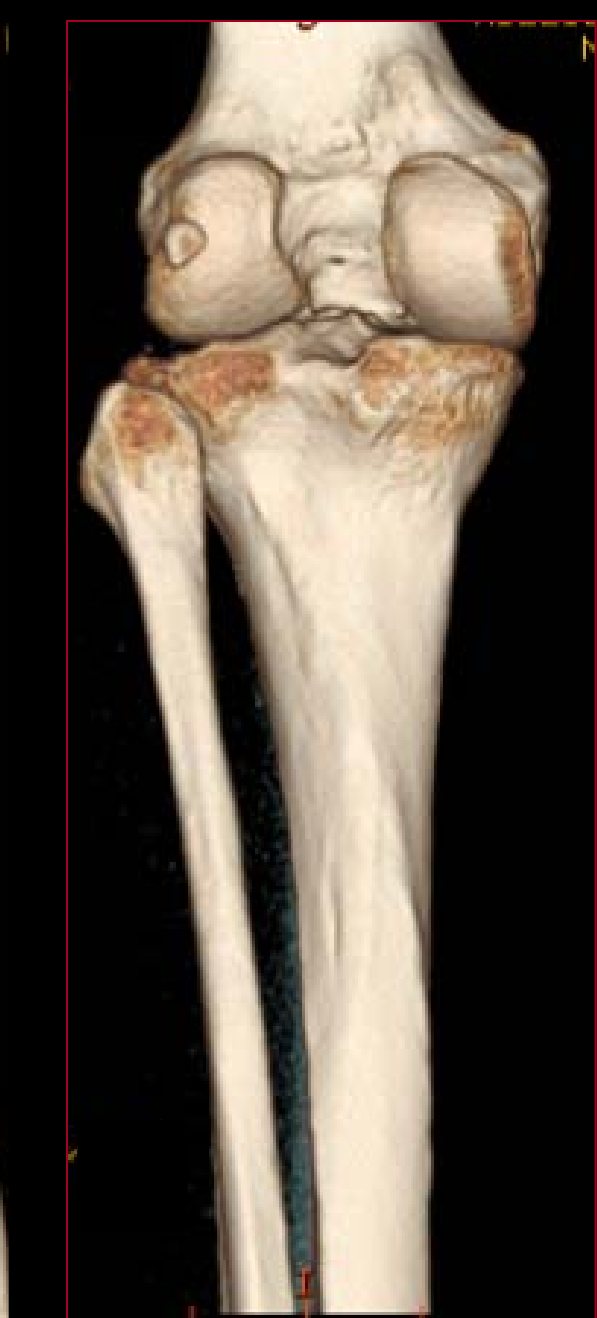
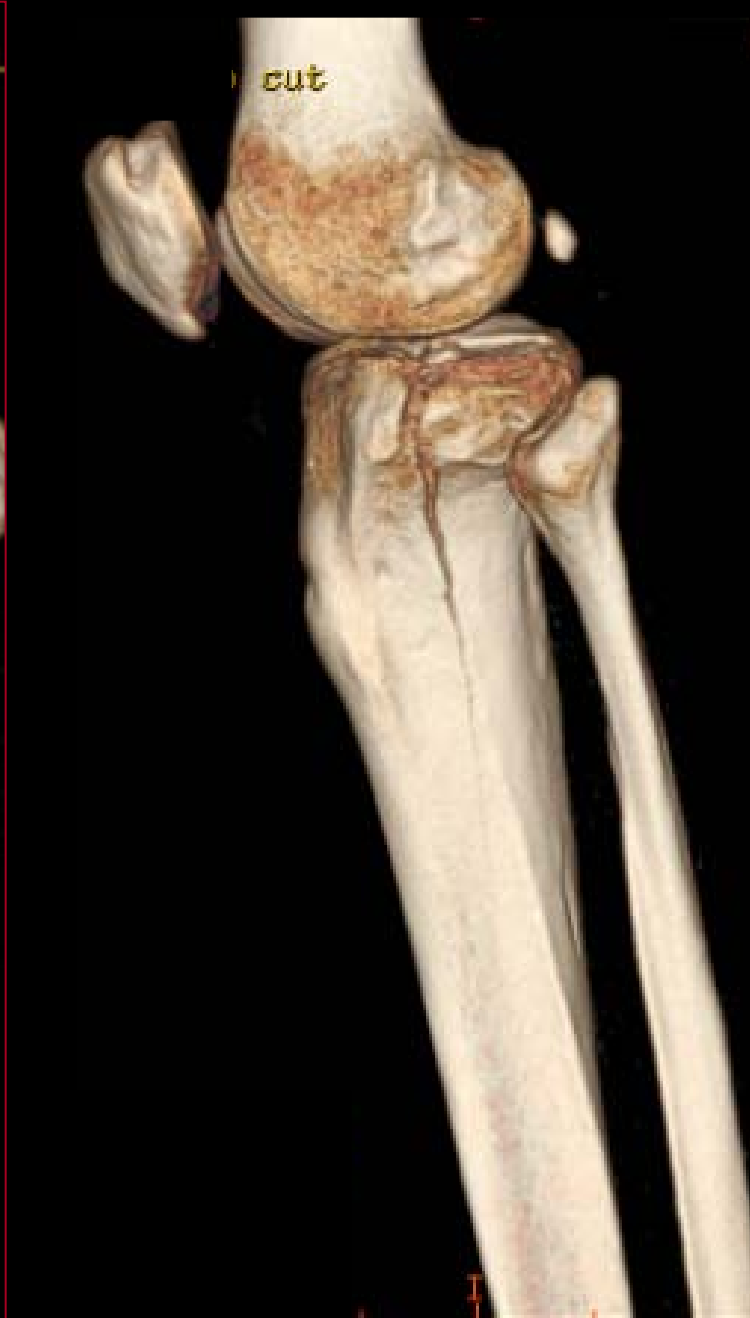
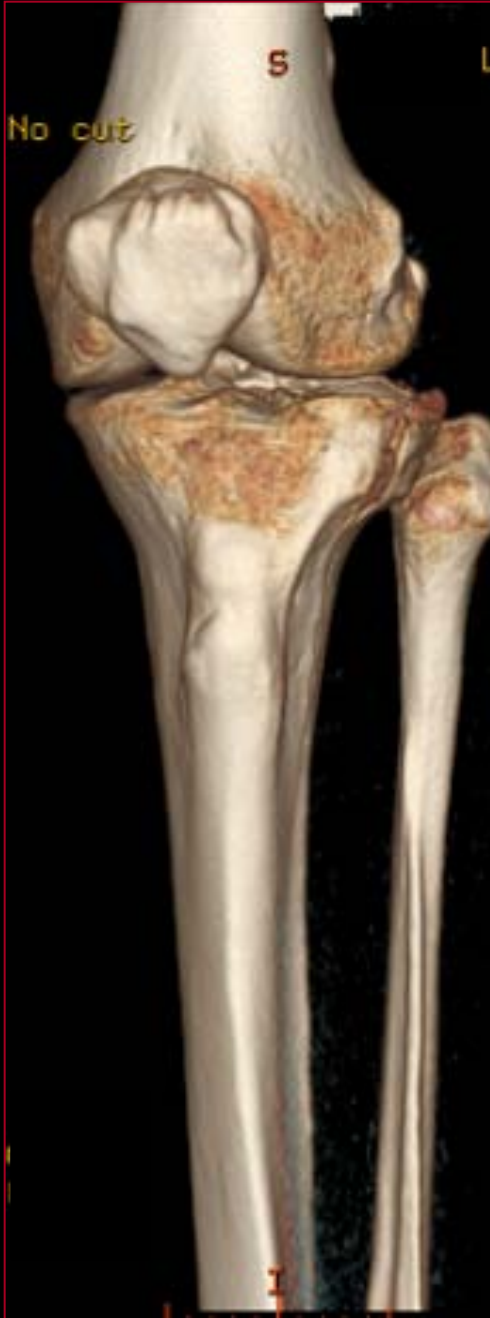Tibia/Fibula AP



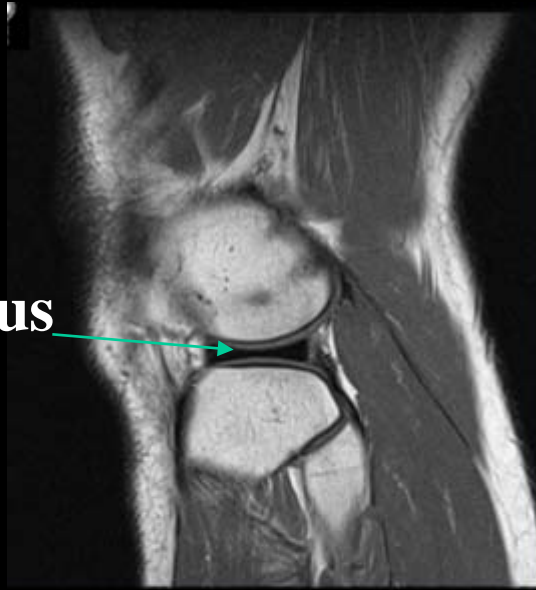LEFT TIBIA/FIBULA LAT

3D CT Knee, Tibia and Fibula

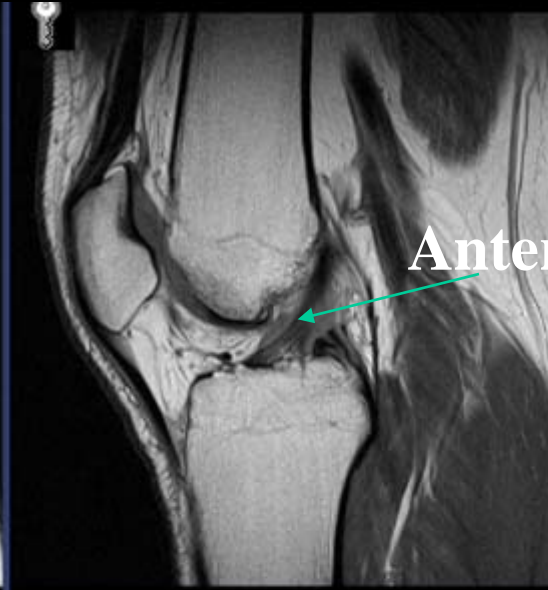


MRI Knee Sagittal

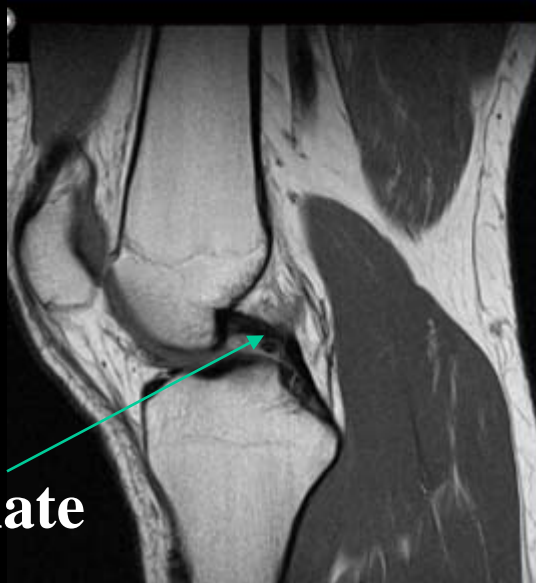
Lateral Meniscus



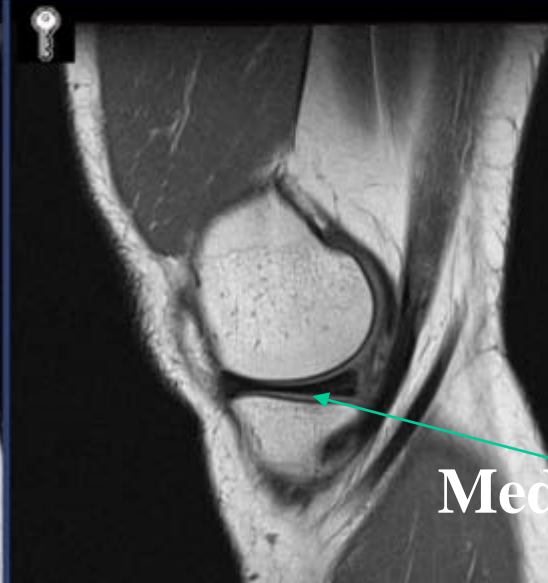Anterior Cruciate

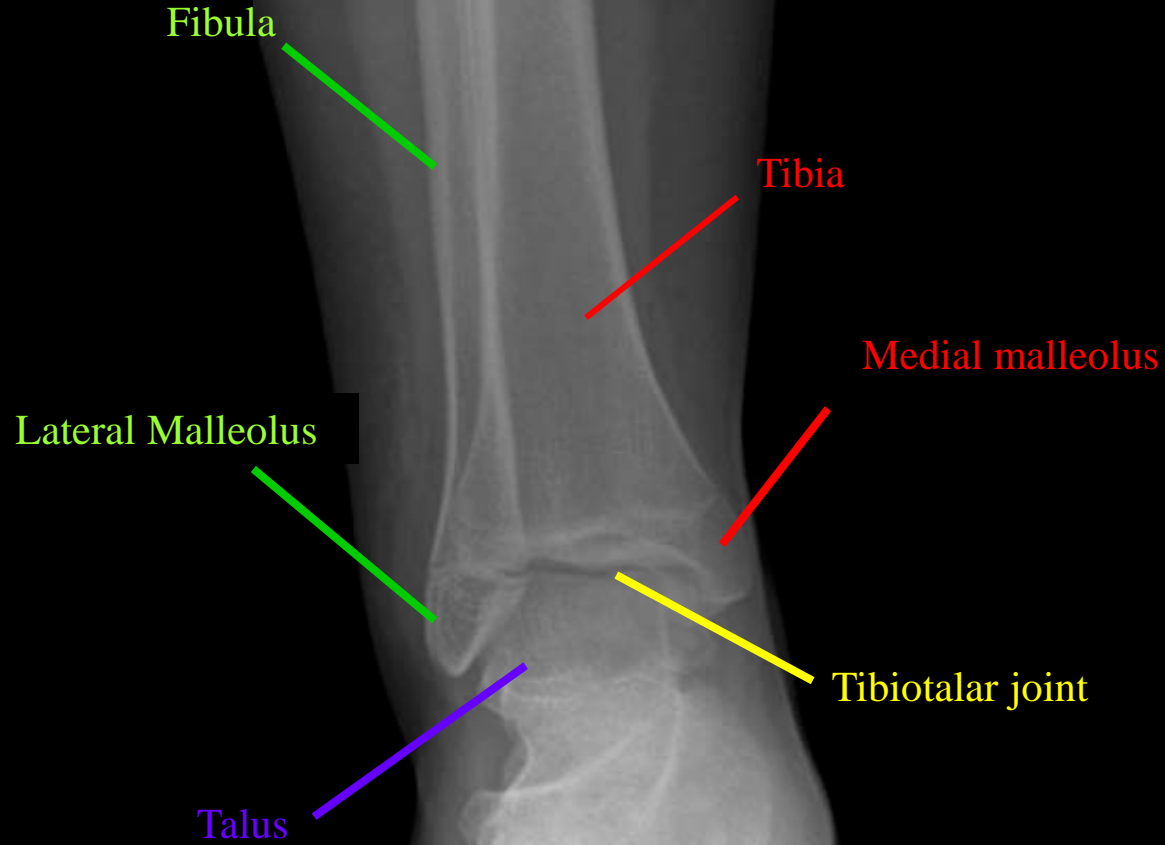
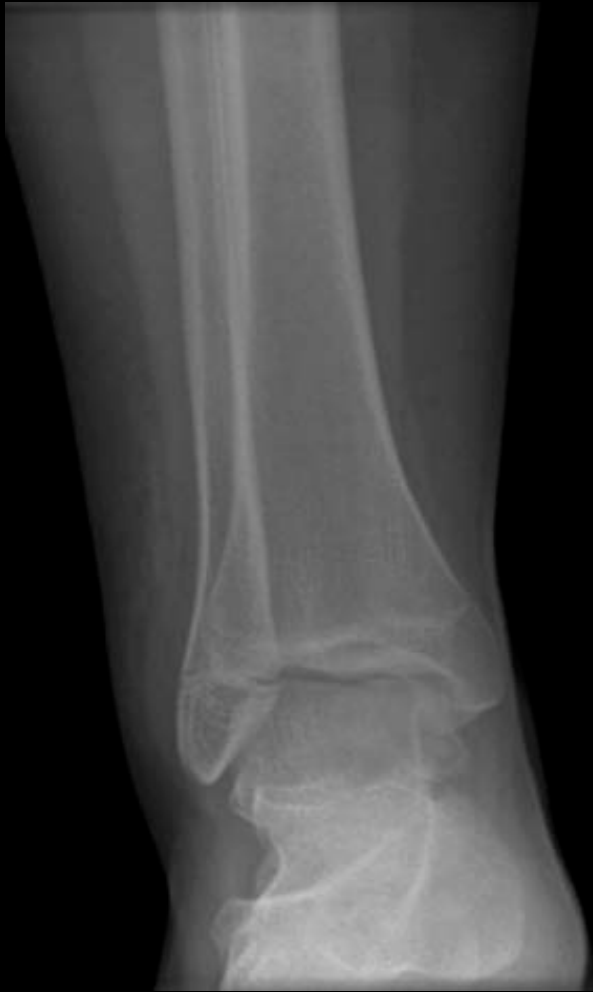

Posterior Cruciate

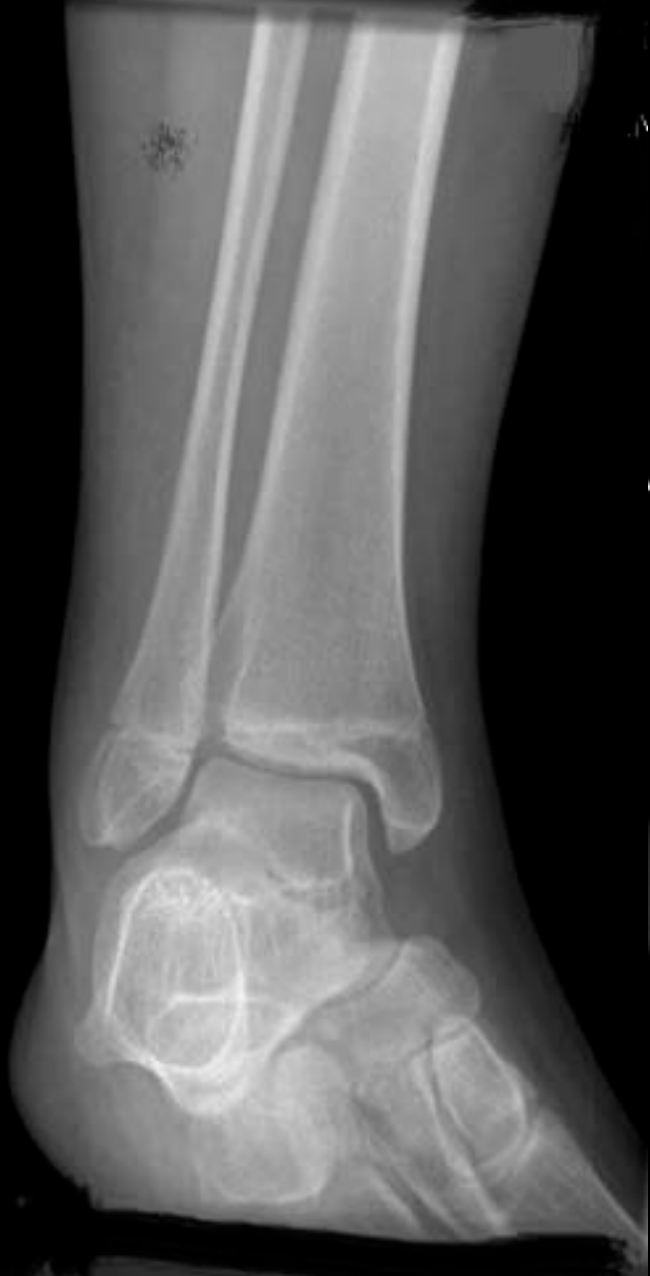

Medial Meniscus





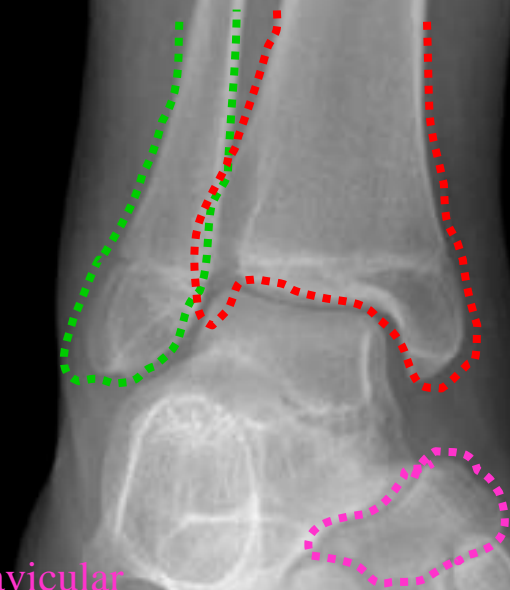
Ankle AP



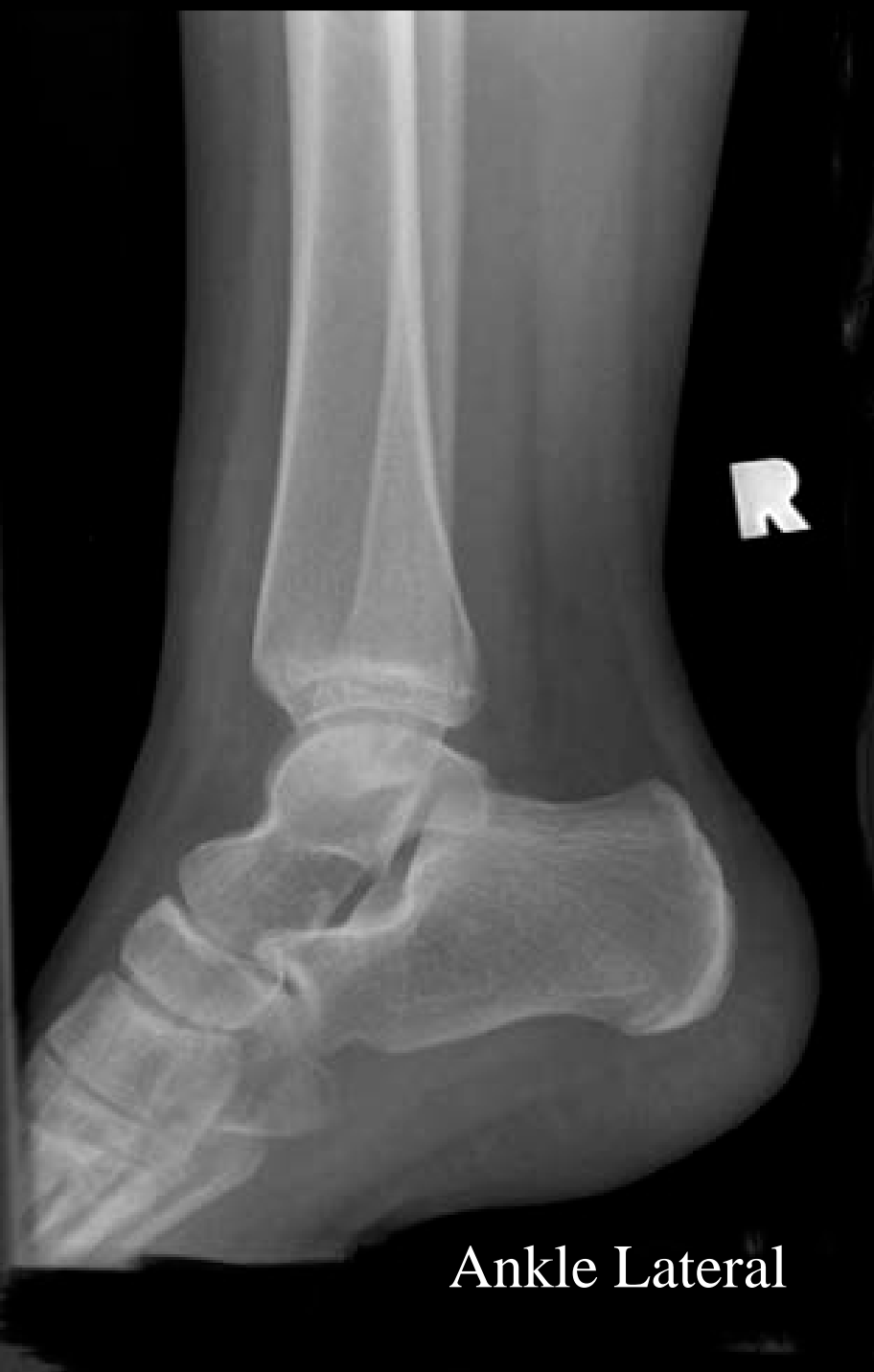Fibula

Tibia

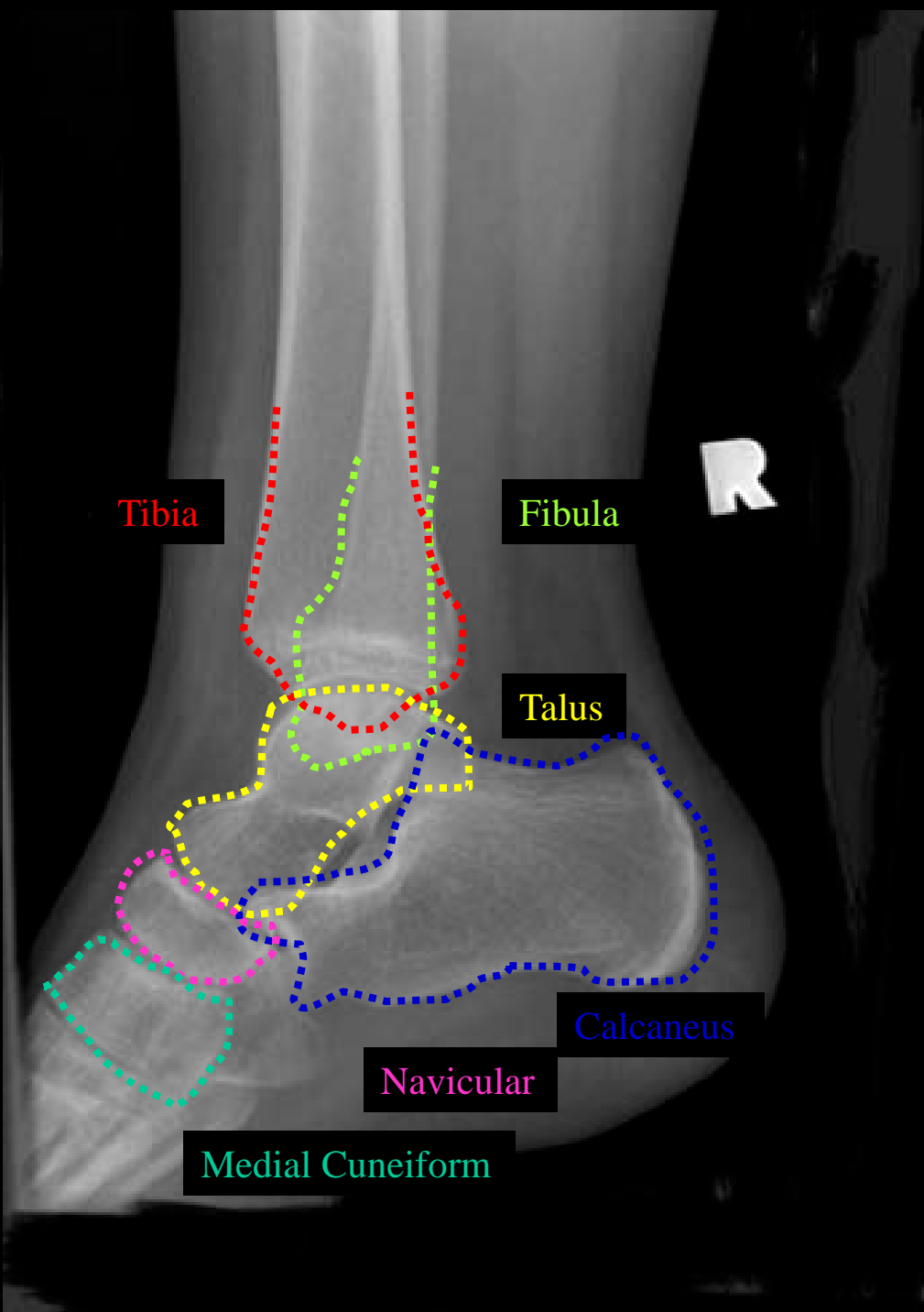
Navicular



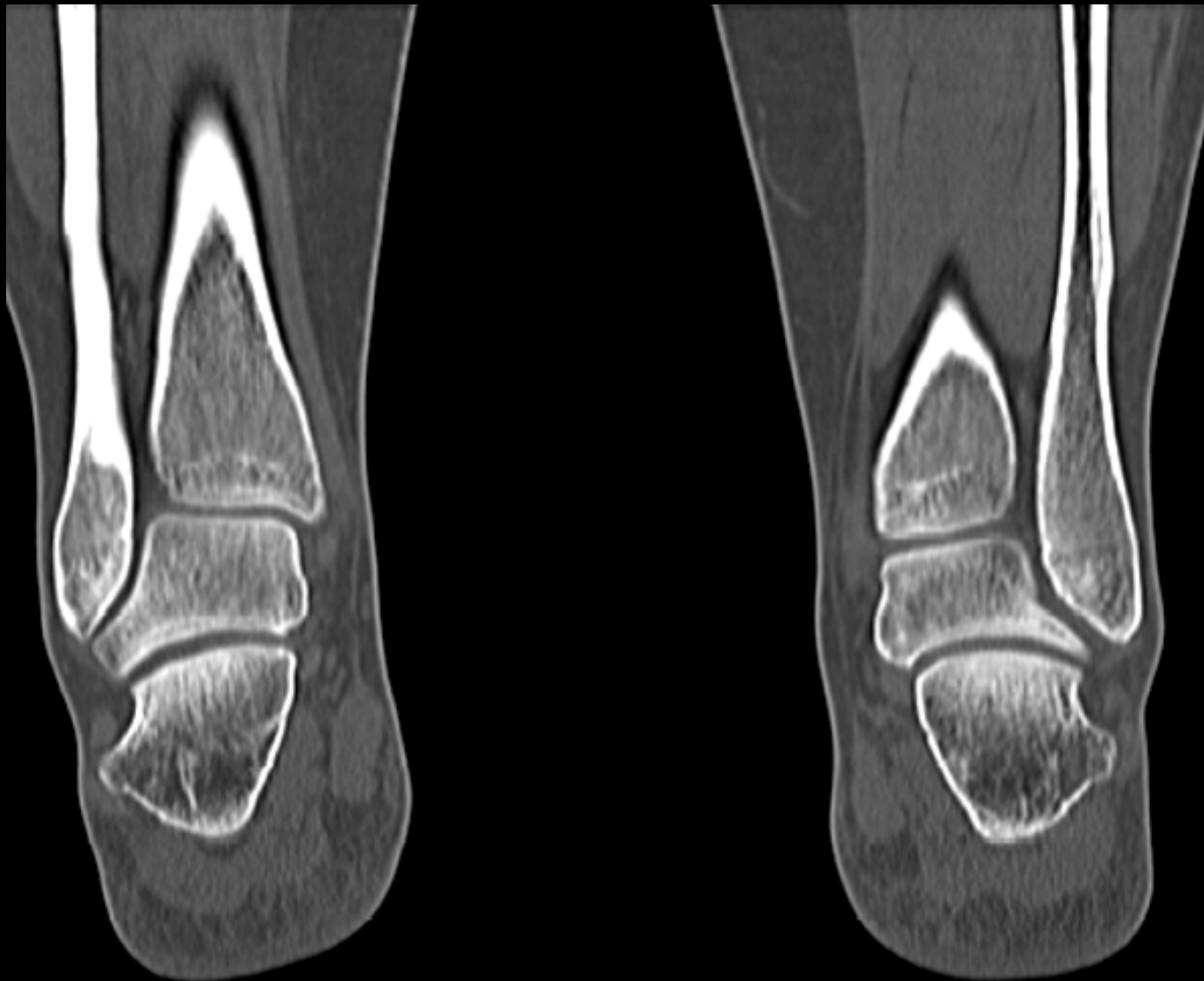
Ankle Oblique

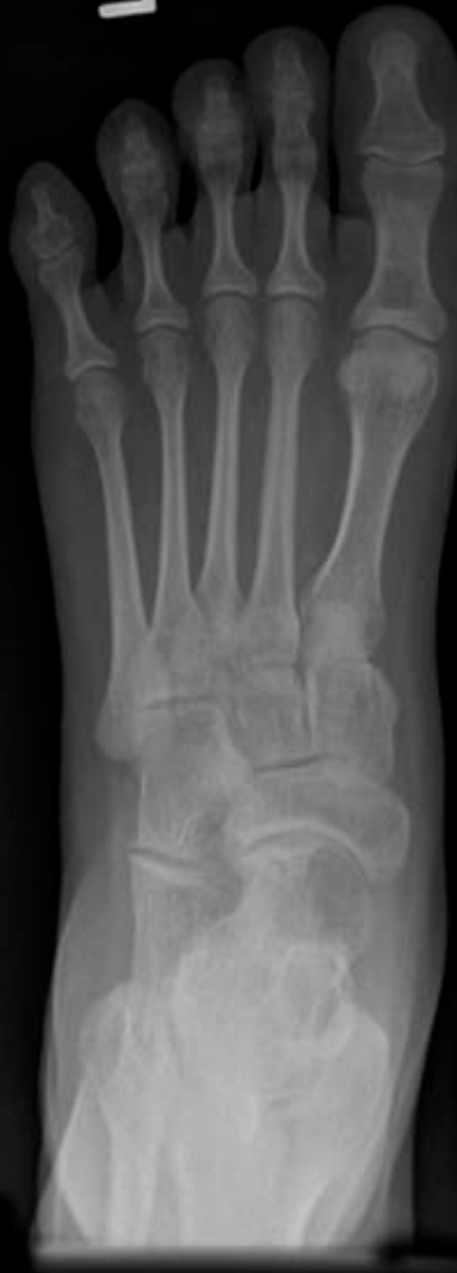

Ankle Lateral



Coronal CT Ankles





Lateral Cuneiform

Medial Cuneiform

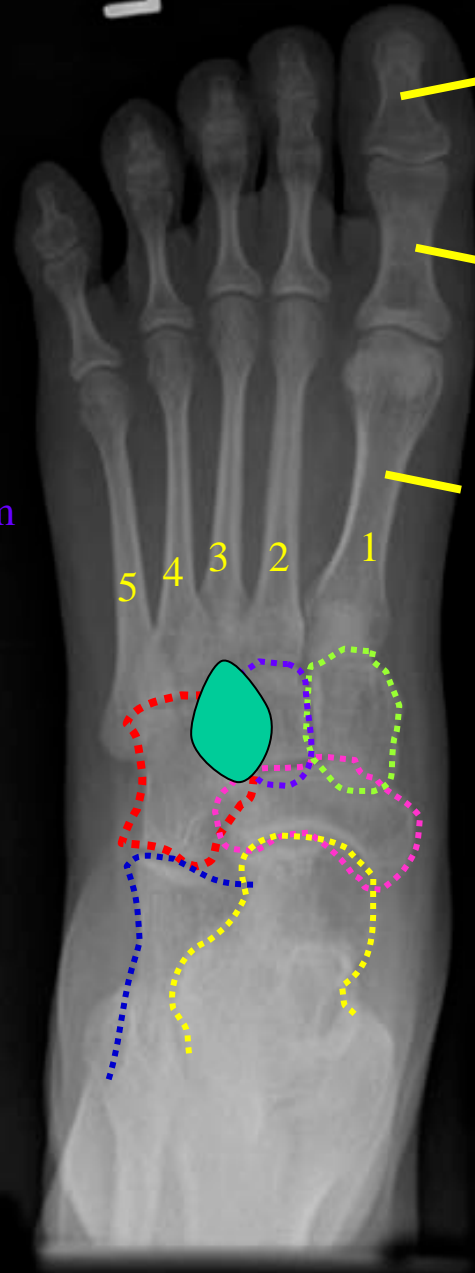
Cuboid

Intermediate Cuneiform

Navicular

Calcaneus

Talus



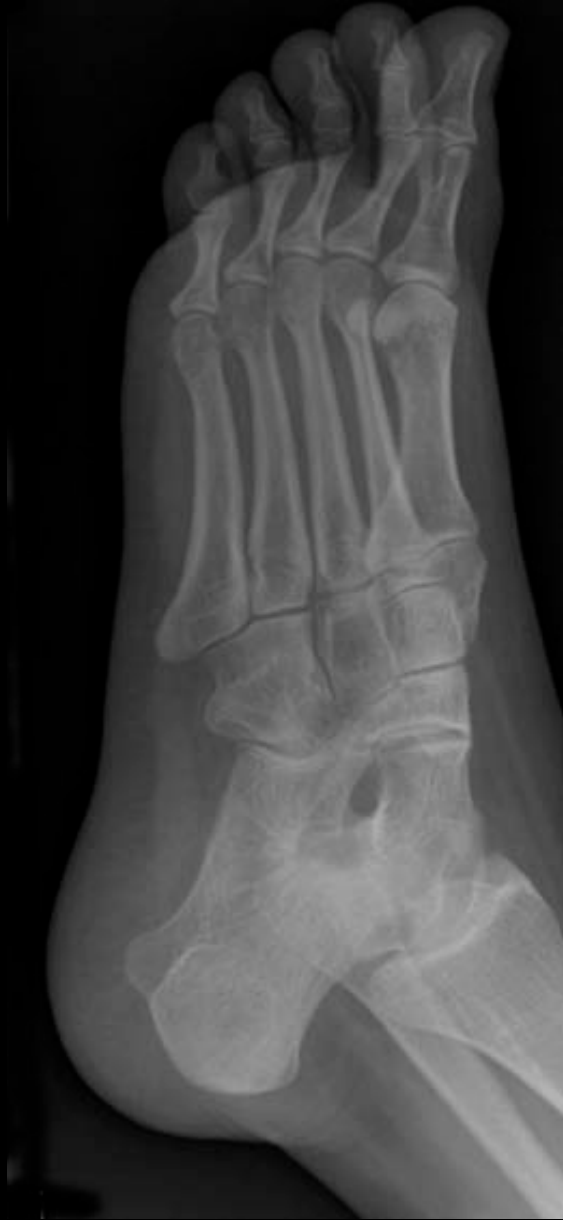Distal Phalanx

Proximal Phalanx

Metatarsals

5 4 3 2 1

Foot AP



Lateral Cuneiform

Medial Cuneiform

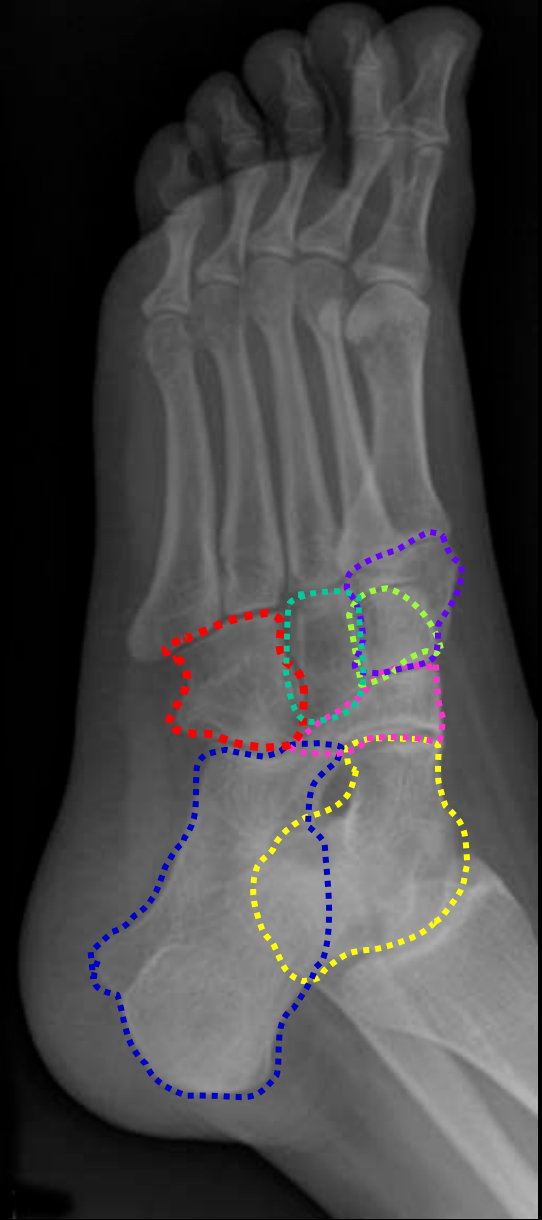
Cuboid

Intermediate Cuneiform

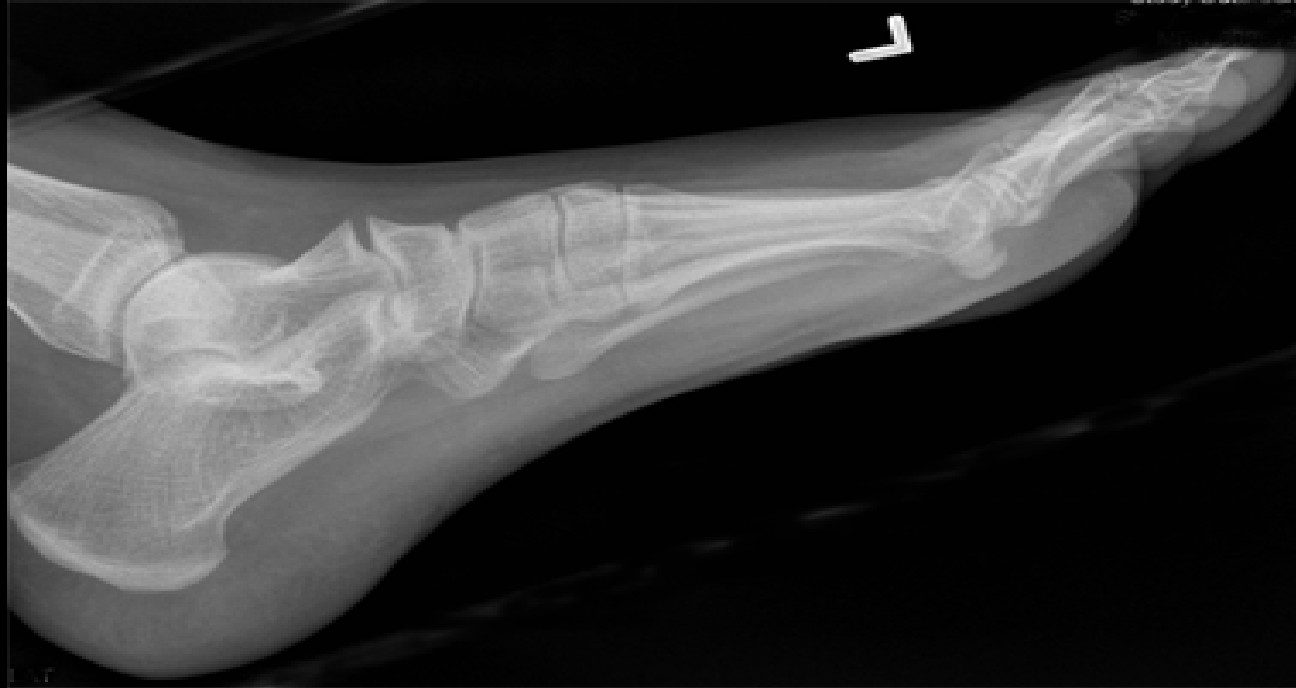Navicular

Calcaneus

Talus



Foot Oblique



Lateral Cuneiform

Medial Cuneiform

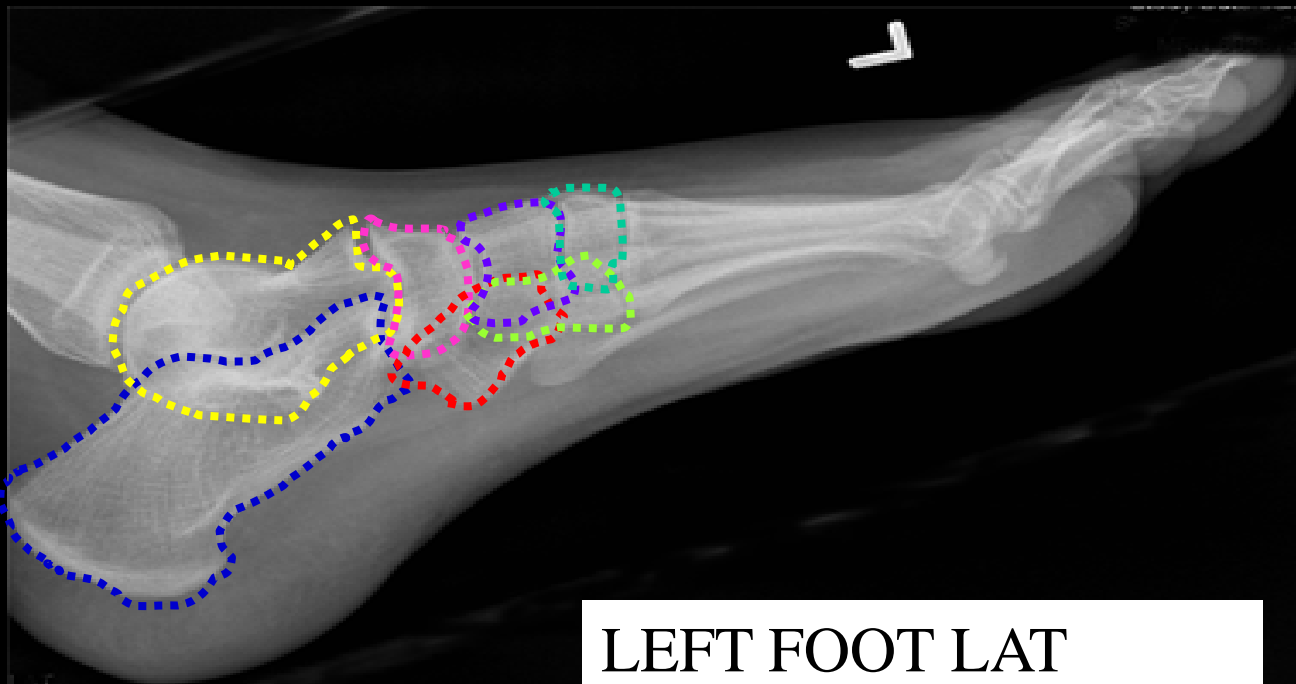
Cuboid

Intermediate Cuneiform

Navicular

Calcaneus

Talus



LEFT FOOT LAT